

Double suturless hepaticojejunostomy

E. Brătucu, D. Straja, C. Cirimbei, M. Alecu, D. Nechita

1st Surgical Clinic, Bucharest Oncological Institute, Carol Davila University School of Medicine, Bucharest, Romania

Rezumat

Hepaticojejunostomia dublă fără sutură

În leziunile iatrogene de cale biliară principală, în special atunci când leziunea se află deasupra joncțiunii canalelor hepatice, chirurgul este nevoit să folosească două bonturi biliare scurte și cu diametru redus. În consecință este necesară efectuarea a două anastomoze separate folosind o ansă în "Y" realizând o dublă hepaticojejunostomie. Dificultățile tehnice se accentuează atunci când canalele biliare sunt subțiri și despărțite între ele pe mai mult de 2 cm. Pentru această situație am realizat o dublă hepaticojejunostomie fără sutură prin apozitia celor doi parteneri anastomotici menținuți în contact prin tracțiune continuă exercitată prin intermediul celor două proteze hepato-bilio-jejunale.

Cuvinte cheie: leziuni iatrogene biliare, hepaticojejunostomia fără sutură

Abstract

In iatrogenic lesions of the main bile duct, especially when the injury is above the level of the hepatic bifurcation, the surgeon ought to use two short and thin biliary stumps. It is necessary to perform separate anastomoses, using a "Y loop" and creat-

ing a double hepaticojejunostomy. Technical difficulties increase when the biliary ducts are thinner, tighter and separated from one another for a distance more than 2 cm. In such case we have attempted to develop a double sutureless hepaticojejunostomy by simply keeping the bilioenteric partners in apposition with continuous traction exerted via the biliary stents.

Key words: biliary injuries, suturless bilio-enteric anastomosis

Introduction

Common bile duct injury is seen most frequently after coledochectomy – about 0,1 %. More than anything else, the cardinal factor is the failure to identify the common bile duct. It is more painful when such difficulties are encountered: acute cholecystitis bleeding, obese patient, distorted and fibrous hepatic pedicle, variants of bilio-vascular anatomy, internal biliary fistulas. There are three kinds of lesions: partial or total loss of integrity by transection, stenosis following ligation and their combination. The most difficult repair is at or above the level of hepatic bifurcation. The surgeon ought to find healthy ducts above the point of damage.

Frequently the surgeons prefer to use Roux-en-Y hepaticojejunostomy at the first attempt. In most instances is the "holly plane". Sometimes the biliary stump is too short, thinner and tighter. Proximal to the bifurcation the damage is more difficult to repair, concerning two or three thin, friable and undilated ducts, inappropriate for a safe anastomosis. The surgeon has to perform separate anastomoses in a very disturbed anatomy of the region. It is not the aim of our presentation to discuss the need to stent the stomas and to achieve a mucosa-to-mucosa

Corresponding author: Prof. dr. Eugen Brătucu
1st Surgical Clinic, Oncological Institute,
Carol Davila University School of Medicine
Bucharest, Romania
Tel. + 4221.227.15.90, Fax + 4221.227.10.11
E-mail: lasimion@yahoo.com

anastomosis. After lowering the hilar plate it is possible to appreciate the anatomic arrangement of the right and left hepatic ducts and to recognize if exist some independent segmental ducts. Sometimes a segmental duct from the right territory empty into the left hepatic tree, just proximal to the bifurcation. The caudate lobe drains inconstantly directly into the bifurcation or into one of the hepatic ducts. These ducts must be incorporated into the reconstruction, not left out of the bilio-enteric bypass. It is more difficult to locate the right hepatic duct. It has a short extrahepatic course. We intend to deal with a very high damage, proximal to the bifurcation, the hilar lesion separating the right and left systems from one another for a distance of 4 cm. In such cases it was chosen a procedure that brings the jejunal stomas in contact with the hepatic ducts, without placing stitches to avoid more damage of the biliary stumps.

The method used by us was published in 1998 based on the first 7 cases (1). Sutureless hepaticojejunostomy was also reported by other authors, using a special intraluminal tube and evaluating the safety and effectiveness of this kind of techniques (6,7). It represents a saving solution for patients with the biliary duct inappropriate for a safe standard anastomosis. Now, it was our first case in which we used a double hepatico-jejunostomy without suture.

Case report

T.M., female, 62 years old, admitted in our department 14 days after a colecystectomy by classic approach, after the conversion of a laparoscopy for acute lithiasic colecistitis. The fourth day after surgery it was recorded a daily 800 ml bile leak. Reoperation was decided and performed by the same surgeon. The common bile duct (CBD) is completely interrupted with an important biliary tissue loss. It was possible to identify a hilar injury that separates the right and left systems by transection above the bifurcation. At times,

the surgeon adapted a reasonable attitude inserting tubes in each hepatic duct with the aim to obtain external biliary fistulas. The patient was referred to our department after 10 days of drainage. We recorded no abdominal sepsis, no cholangitis and no postoperative jaundice: WBC – 9,73 K/UL, RBC – 3,82 M/UL, HGB – 12,1 g/dl, HCT 36,2 0/00, PLT – 418 K/UL, AST – 58 U/L, ALT – 183 U/L, GGT – 472 U/L, ALP – 175 U/L, LDH – 250 U/L, TBIL – 0,33 mg/dl, normal coagulation results.

The native abdominal IRM showed 2 tubes inserted into the biliary stumps, very high in the hilar plate, moderate dilatation of the right biliary system (Fig. 1).

After 48 h, the patient underwent reoperation using the same subcostal approach. No collection was encountered.

The hilar plate was exposed and the ducts identified, recording a 4 cm distance between them. It was not possible to obtain a generous length of ducts. The distal biliary stump was previously legated, demonstrating an important loss of length. The single reasonable approach was the Roux-en-Y hepatojejunostomy for each duct. The caliber of ducts was very small (3-4 mm) and their wall was unsuitable for a safe anastomosis, avoiding fistulas. The drainage tubes were removed. The main tenet regarding repair was the use of sutureless bilio-enteric splinted anastomosis. Our technique is described in Digestive Surgery, 1998, 15: 663-664. We used transhepatic tubes (Foley) to splint bilio-enteric anastomoses and to keep in touch the biliary and jejunal partners (Fig. 2, 3).

The postoperative course was uneventful. The biliary transhepatic tubes drained daily about 300 ml. Intraoperative cholangiography was used showing no biliary leak and the correct position of the Foley catheters. We used two no. 10 Ch Foley catheters. Finally, the catheters stent the double hepatico-jejuno anastomosis. The Foley's balloon is enabling the postoperative control of its position. The jejunal stoma is brought in contact with the biliary duct by exerting a

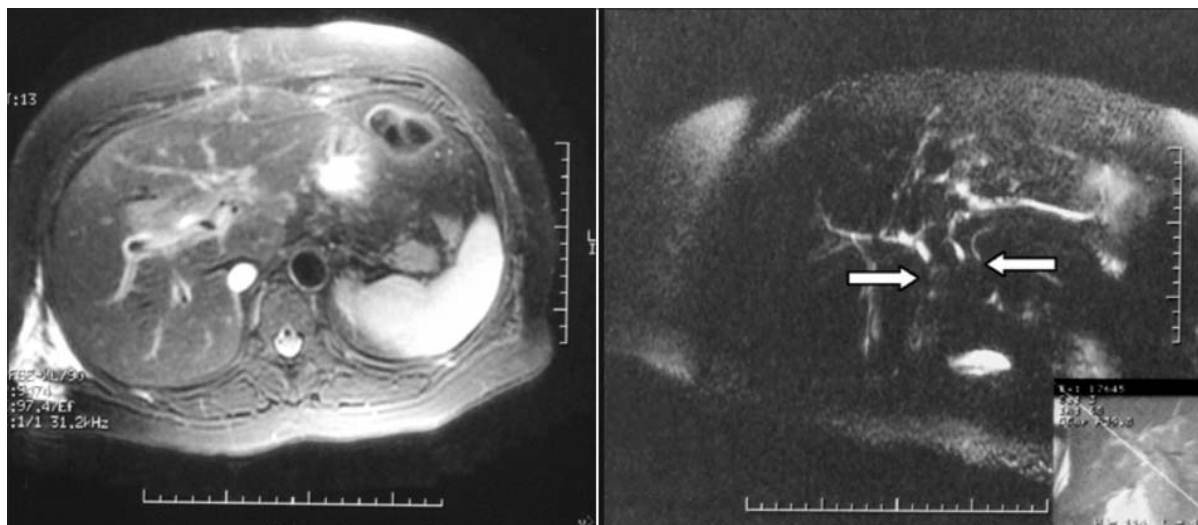


Figure 1. Preoperative IRM – Biliary stumps splinted and absence the main duct. White arrows – drains in the biliary stumps

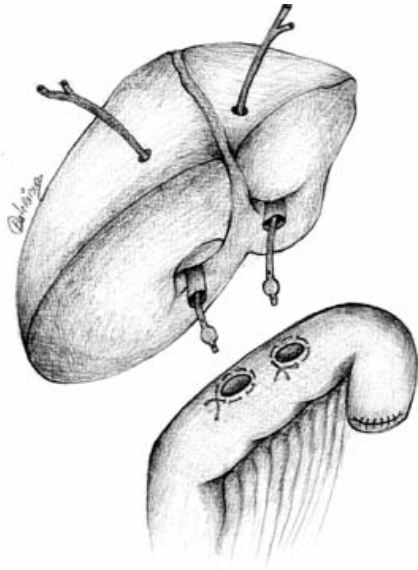


Figure 2. 1st step to perform a suturless anastomosis

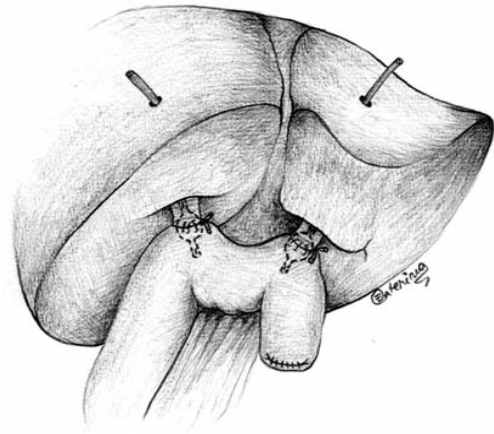


Figure 3. 2nd step of the bilio-enteric anastomoses: the stomas partners keep in contact by exerting traction on the tubes

continuous traction on the Foleys that splint the anastomosis.

The patient was discharged the 20th postoperative day. The continuous traction was suppressed on the 14th postoperative days, maintaining the balloons inflated to eventually enable corrective measures. The splint drains were clamped on the 16th postoperative day and removed on the 46th day, after a final cholangiography and balloons deflation. (Fig. 4, 5)

The clinical evaluation performed 4 months later showed good medium term results: AST – 39 U/L, ALT – 47 U/L, TBIL – 0,38 mg/dl, WBC – 5,99 g/dl, RBC – 4,6 M/UL, HGB – 13,5 g/dl, HCT – 42,2%. One year after surgery colangi-M.R.I. showed the double hepaticojejunostomy working properly, without any clinical or biochemical alteration. (Fig. 6)

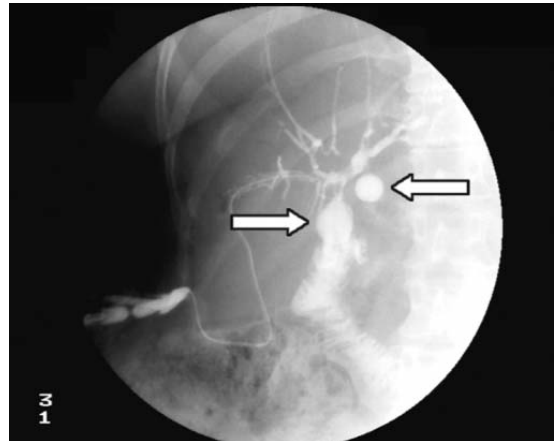


Figure 4. Cholangiographic control: free bilio-enteric passage. Arrows – the Foley balloons (the 13th p.o. day)

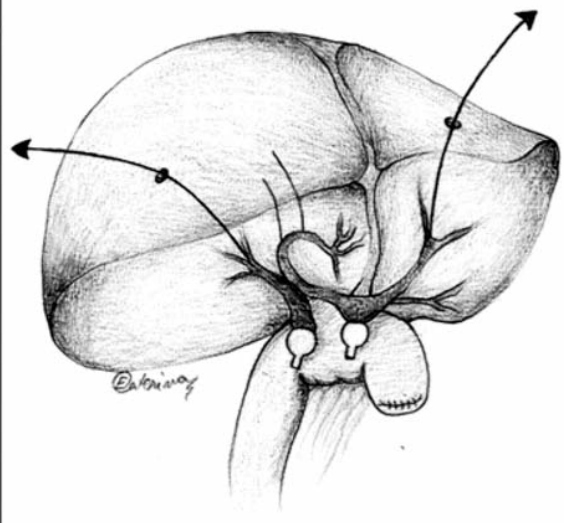
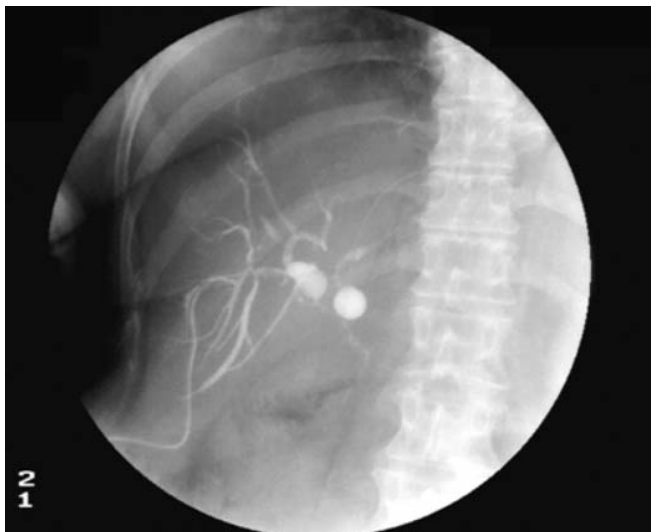


Figure 5. Cholangiographic control before removing splints (46th p.o. day) - Schematic diagram - postoperative cholangiographic biliary map (on the right)

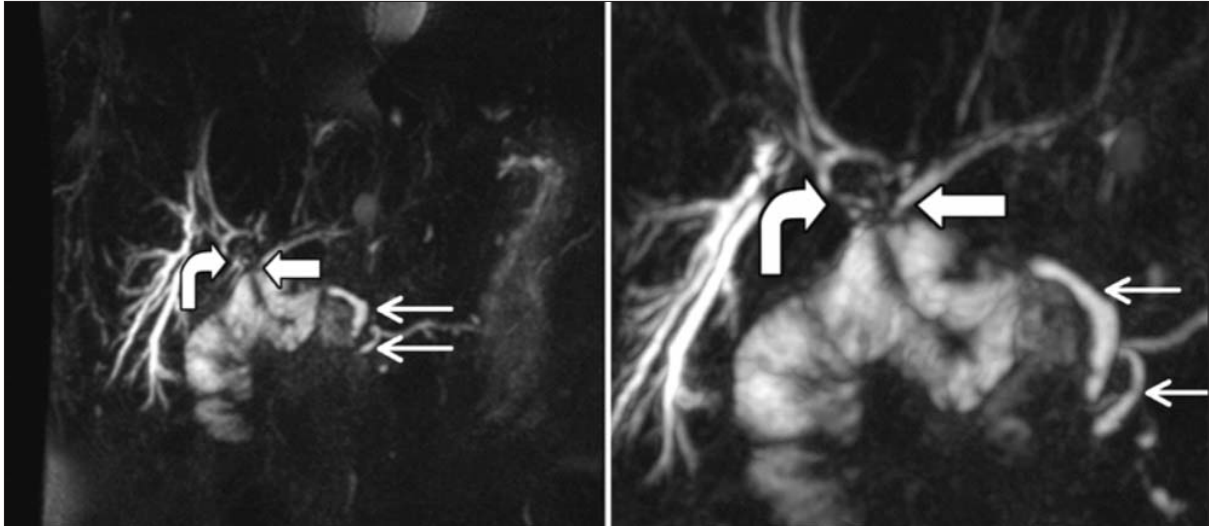


Figure 6. Colangio- M.R.I.. One year after surgery. On the left, white large arrows: the hepatico-jejunal anastomosis, white thinner arrows: main bile duct stump and the main pancreatic duct. On the right: same magnified image

Discussion

All the surgeons agree with the fact that bile duct injuries ought to be repaired successfully at the first attempt. Sometimes the biliary stump is inappropriate for a standard hepatico-jejunostomy. In this case, tubes are frequently used to stent anastomoses. One of the surgeon's options is the transhepatic drainage (2,3,4,6).

Inspired by this attitude we performed an anastomosis without using stitches. The two anastomotic partners are keeping in contact by inserting a Foley catheter into the biliary stump, with the tip inside the jejunal loop. Then, inflating the balloon and performing a purse string around the loop aperture, by using a continuous traction on the Foley, the jejunum is kept in touch with the biliary duct.

Our method is a saving solution in well selected cases in which a safe standard anastomosis is risky. It deserves attention because of its simplicity and relative technical rapidity.

References

1. Bratucu E, Ulmeanu D, Bota D. Hepaticojejunostomy without suture. *Dig Surg.* 1998;15(6):663-4.
2. Burlui D, Ratziu O: Extra-peritoneal biliary drainage through a repermeabilized umbilical vein. *Presse Med.* 1971;79(9):408-9. (Article in French)
3. Cameron J, Gayler BW, Zuidema GD. The use of silastic transehepatic stents in benign and malignant biliary strictures. *Ann Surg.* 1978;188(4):552-61.
4. Praderi RC. Twelve years experience with transhepatic intubation. *Ann Surg.* 1974;179(6):937-40.
5. Schirmer WJ, Rossi RL, Hughes KS, Munson JL, Braasch JW. Common operative problems in hepatobiliary surgery. *Surg Clin North Am.* 1991 Dec;71(6):1363-89.
6. Wexler MJ, Smith R. Jejunal mucosal graft: a sutureless technique, for repair of high bile duct strictures. *Am J Surg.* 1975; 129(2):204-11.
7. Cai X, Lin H, Yu H, Liang X, Zhu L, Wang Z, Peng S. Novel sutureless cholangiojejunostomy: initial experience with 11 cases. How I do it. *Am J Surg.* 2008;195(2):273-6.