

## Major Surgical Resections in Abdominopelvic Sarcomas: Clinical Features and Results of 38 patients: A Tertiary-Center Experience

Murat Kalin<sup>1</sup>, Omer Faruk Ozkan<sup>1</sup>, Ozgul Duzgun<sup>1</sup>, Hanife Seyda Ulgur<sup>1</sup>, Muhammed Kadir Yildirak<sup>1</sup>, Resul Sobay<sup>1</sup>, Gurkan Kiran<sup>2</sup>

<sup>1</sup>University of Health Sciences (Saglik Bilimleri University), Department of General Surgery, Umraniye Training and Research Hospital, Istanbul, Turkey

<sup>2</sup>Bezmialem Vakif University, Istanbul, Turkey

\*Corresponding author:

Muhammed Kadir Yildirak, MD  
University of Health Sciences Umraniye  
Training and Research Hospital,  
Department of General Surgery  
Umraniye EAH, 34764, Elmalikent  
Umraniye, 34764 Istanbul, Turkey  
Phone: +905414872126  
E-mail: kadiryildira@gmail.com

### Rezumat

#### *Rezecții chirurgicale majore în sarcoamele abdominopelvine*

*Introducere:* Sarcoamele cu origine mezenchimală localizate în cavitatea abdominală sau spațiul retroperitoneal sunt rare. Acestea pot atinge dimensiuni mari din cauza debutului nespecific și tardiv al simptomelor. Scopul acestui studiu este de a prezenta rezultatele a 38 de cazuri de sarcoame localizate intra-abdominal.

*Metode:* Studiul include 38 de pacienți, ale căror date au fost înregistrate și analizate complet în mod prospectiv. Au fost evaluate rezultatele demografice, statusul primar-recurent al bolii, tipul rezecției (R0-1-2), rezecțiile suplimentare de organ, ratele de morbiditate și mortalitate, aplicarea HIPEC, rezultatele histopatologice și supraviețuirea generală.

*Rezultate:* În cazul a 38 de pacienți s-a intervenit chirurgical pentru diagnosticul de sarcom de țesut moale cu localizare intra-abdominală. Vârsta medie a pacienților a fost de  $57,63 \pm 15,38$ . Tumorile au fost localizate la nivel retroperitoneal (28%), abdominal (58%) și visceral (12%). Dimensiunea medie a tumorii a fost de  $12,96 \text{ cm} \pm 9,62$ . În 27 de cazuri (71%) s-a practicat rezecție R0, în 7 cazuri (18%) s-a practicat rezecție R1, iar în 4 cazuri (10%) s-a practicat rezecție R2. În plus, sarcomatoza a fost identificată în 6 cazuri pentru care s-au efectuat intervenții chirurgicale citoreductive + HIPEC. Ratele de mortalitate și morbiditate în primele 30 de zile au fost de 10,5% (4 pacienți) și, respectiv, 44% (17 pacienți).

*Concluzie:* Rezecția chirurgicală reprezintă tratamentul standard

Received: 14.03.2022

Accepted: 12.05.2022

al sarcoamelor intra-abdominale. Cea mai importantă etapă în managementul acestei afecțiuni este discutarea acestor cazuri în comisiile multidisciplinare din centrele cu experiență în această boală în ceea ce privește prognosticul și recidiva locală. Strategia de tratament ar trebui stabilită pe baza acestor discuții.

**Cuvinte cheie:** sarcom, abordare multidisciplinară, rezecție chirurgicală

## Abstract

*Introduction:* Sarcomas with mesenchymal origin located in the abdominal cavity or retroperitoneal space are rare. They might reach large dimensions due to the non-specific and late onset of clinical symptoms. In this study we aim to provide the outcomes of 38 cases.

*Methods:* Thirty-eight patients, whose data had been registered and analyzed completely in a prospective manner, were enrolled in the study. Demographic Findings, Primary-Recurrent Status of the disease, surgical method applied (R0-1-2), additional organ resections, Morbidity and Mortality rates, HIPEC application, Histopathological results and overall survival outcomes during follow-up were evaluated in the enrolled cases.

*Results:* Thirty-eight (38) patients were operated on due to soft tissue sarcomas located in the abdominal and retroperitoneal area. The mean age of patients was  $57.63 \pm 15.38$ . The localization rates of retroperitoneal, abdominal and visceral tumors were 28%, 58%, and 12%, respectively. The mean tumor size was  $12.96 \text{ cm} \pm 9.62$ . Twenty-seven patients (71%) underwent R0 resection, 7 patients (18%) underwent R1 resection, 4 patients (10%) underwent R2 resection. Additionally, sarcomatosis was detected in 6 patients and these patients underwent Cytoreductive Surgery+HIPEC. The first 30-day mortality and morbidity rates were 10.5% (4 patients) and 44% (17 patients), respectively.

*Conclusion:* Surgery is the gold standard treatment of this condition. The most important stage in the management of the condition is the discussion of these cases in multidisciplinary teams in centers experienced in this disease in terms of prognosis and local recurrence and deciding on the treatment strategy based on these discussions.

**Key words:** sarcoma, multidisciplinary approach, surgical resection

## Introduction

Tumors with mesenchymal origin which constitute the non-epithelial tumors of the abdomen are rare. Although genetically they might develop in childhood, generally they affect adults. Due to their retroperitoneal localization, apart from findings such as obstruction and pain which occur due to invasion or pressure, they tend to have an asymptomatic course and reach large dimensions. They might also be identified incidentally. Among the tumors of mesenchymal

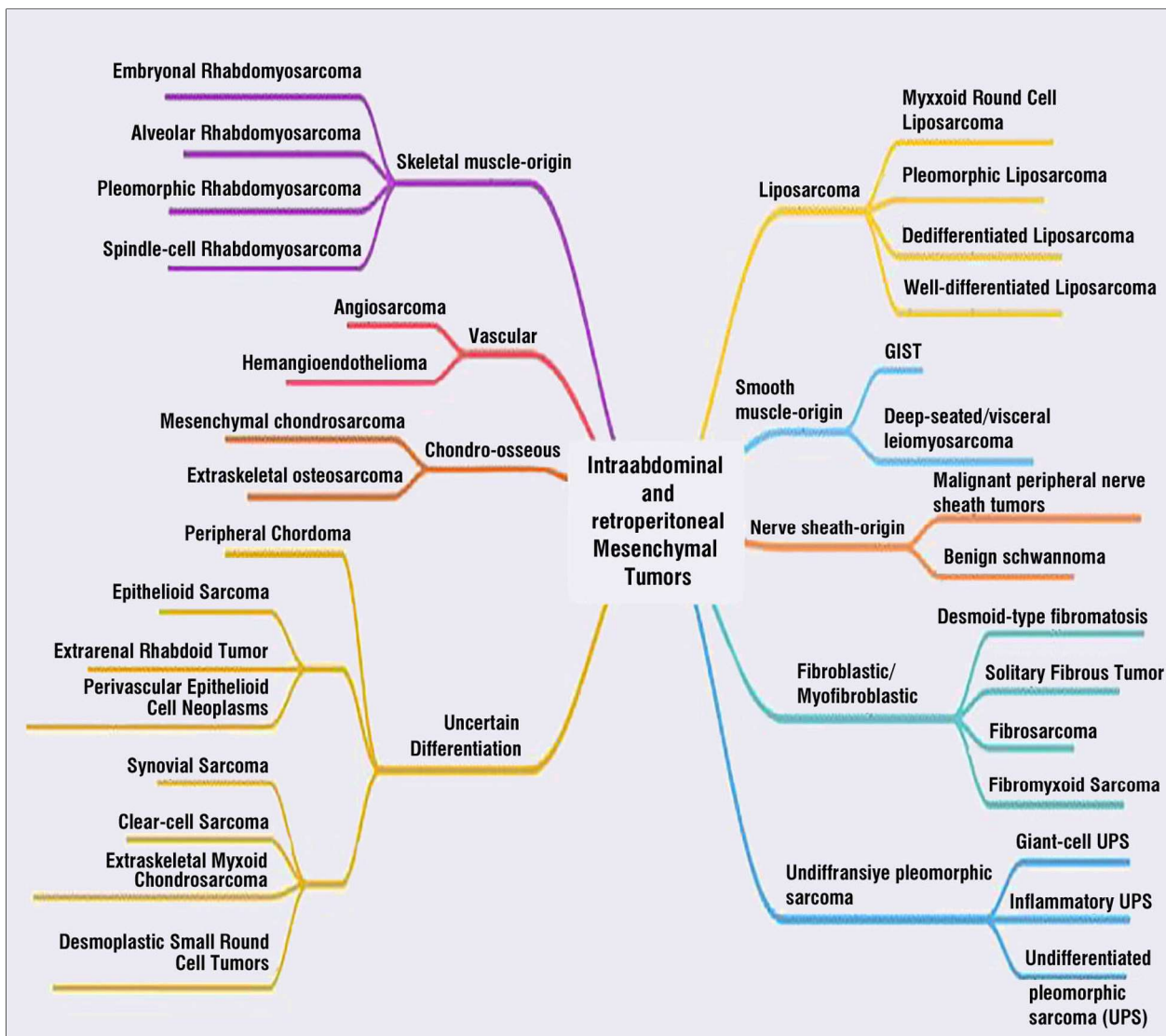
origin, those that exhibit especially malignant behavior are sarcomas. Sarcomas develop from the primitive stem cells of the connective tissue and generally mimic the mesenchymal tissue such as muscle and nerves (1,2). Male to female ratio of sarcomas is 2:1. Sarcomas constitute only 1% of all adult cancers. Sarcomas are generally tumors with high recurrence rates and anatomical location presenting a special importance in treatment choice. In terms of location, they are most commonly encountered in the extremities followed by the retroperitoneal and abdominal

region and least commonly in the head and neck area (3,4,5).

Sarcomas are classified into various histopathological sub-types due to their different behavioral characteristics. According to the classification developed by the World Health Organization (WHO), sarcomas have more than 50 histopathological sub-types. Abdominally, the most common types are leiomyosarcoma, undifferentiated pleomorphic sarcoma, liposarcoma, and malignant peripheral nerve sheath tumors, respectively (Fig. 1). Apart

from these, tumors originating from the nerve sheath such as schwannoma with benign character may also develop (1,6). Staging the tumor and discussing the case in a multi-disciplinary team as the initial evaluation, and then, if possible, en block resection of the sarcoma with intact surgical margins constitute the main treatment approach.

Currently, new chemotherapeutic agents and radiation therapy applications that provide satisfactory results for many types of malignancies are used in both medical oncology and



**Figure 1.** Histopathological Classification of Abdominal Mesenchymal Tumors According to Their Tissue of Origin GIST: Gastrointestinal stromal tumor, UPS: Undifferentiated pleomorphic sarcoma

radiation oncology. However, satisfying outcomes still cannot be achieved in sarcomas with these methods and aggressive surgical interventions remain to be the most important step of the treatment (5). In this regard, the data of patients treated in experienced centers with a high patient volume are of special importance, consequently, in this study, we aimed to present tumors of mesenchymal origin with abdominopelvic location in the light of published literature.

## Materials and Methods

The patients, who were examined between December 2016 and March 2020 by the Oncological Surgery Department of our tertiary center were enrolled and their data with 60 parameters were analyzed by prospective recording in an Excel database. The cases with malignant tumors of mesenchymal origin were extracted from the database and included in the study. The cases lacking any post-operative data or those that were lost to follow-up were excluded from the study. Otherwise, all patients with sarcomas originating from soft tissues including primary and recurrent cases as well as those with vascular origin were included in our study. Prospectively collected data were analyzed for the parameters below.

Demographic Findings: Age, Sex

Clinical Findings: Comorbidities, Symptoms, Primary-Recurrent State

Radiological Findings: Localization, Additional organ involvement

Surgical Treatment: Type of resection (R0-1-2), Additional organ resection, The first 30-day Morbidity and Mortality rates, Post-operative Complications, Concurrent HIPEC application

Adjuvant therapy: Chemotherapy agent administered, radiation therapy

Histopathological Investigation: Tumor Type and Grade, Involvement of resected organs

Follow-up Outcomes: The mean duration of follow-up, Metastasis-Recurrence and Overall Survival rates.

All cases were evaluated by a multidisciplinary team consisting of radiologists, nuclear medicine specialists, medical oncologists and other experts from different specialties experienced in this condition.

## Statistical Analysis

The data extracted were evaluated using SPSS 15.0 (Statistical Package for Social Science) software. The numeric data were evaluated as mean  $\pm$  standard deviation, minimum and maximum values, while the nominal and ordinal data were evaluated as frequency and percentage. Variables that were not normally distributed were given as median and interquartile ranges. Disease-free survival analyzes were conducted with Kaplan-Meier curves. Values below  $P < 0.05$  were considered statistically significant.

## Results

Thirty-eight (38) cases obtained from prospectively recorded data of retroperitoneal and intraabdominal sarcoma patients examined between December 2016 and June 2020 at our tertiary referral center were included in our study. Of 38 cases, 26 (65%) were female and 12 (34%) were male. The mean age for all subjects was  $57.63 \pm 15.38$ , the mean age for male patients was  $51.08 \pm 17.8$  and the mean age for female patients was  $61.04 \pm 13.03$ . Demographics of patients are summarized in *Table 1 (Figs. 2-3)*. When analyzed based on the localization of the tumor, 28% had retroperitoneal, 58% had abdominal and 12% had visceral abdominal tumors. From a clinical perspective 23% of the patients presented to the outpatient clinic with abdominal pain, 28% with abdominal mass, 17% with nonspecific gastrointestinal symptoms such as nausea and vomiting, while 12% presented with vaginal hemorrhage. Apart from that, 15 (39%) cases did not have any symptoms and were identified incidentally.

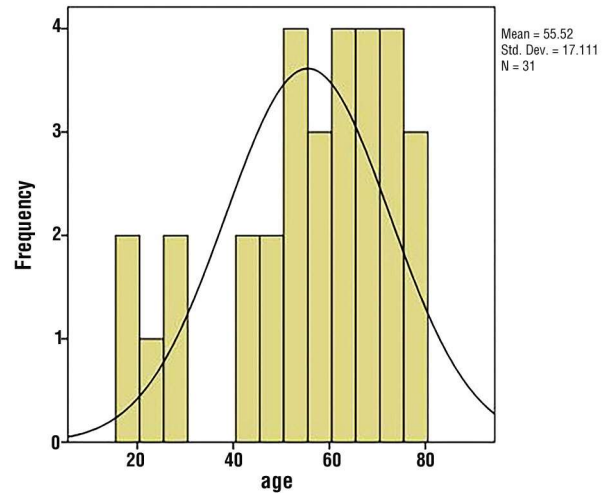
All patients underwent thoracoabdominal CT as well as MRI scanning. Additional CT angiography and MR venography were

**Table 1.** Patient demographics

Characteristics	
Age	55.52 ± 17.1
Female	52.5 ± 1.93
Male	48.30 ± 2.69
Sex	
Female	28 (54.9%)
Male	23 (45.1%)
Localization	
Abdominal	22 (58%)
Retroperitoneal	11 (28%)
Visceral Abdominal	5 (12%)
Symptoms at the time of presentation to the clinic	
Abdominal Mass	28%
Abdominal Pain	23%
Non-specific GIS symptoms (nausea, vomiting)	17%
Vaginal Hemorrhage	12%
Primary	27 (71%)
Recurrence	11 (28%)
Resection	
R0	27 (71%)
R1	7 (18%)
R2	4 (10%)

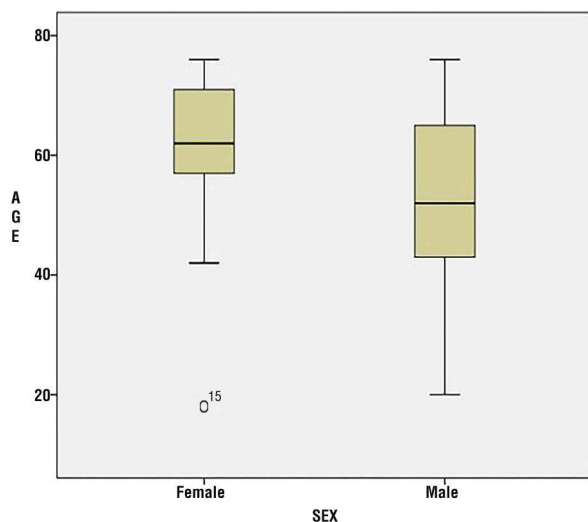
Data are presented as mean ± SD and n (%)

performed for lesions with vascular origin. Also cardiac MRI was performed in a patient with cardiac metastasis. Histopathological evaluation revealed 26% of patients had undifferentiated sarcoma, 15% had GIST, 13% had leiomyosarcoma, 13% had carcinosarcoma, 10% had liposarcoma, 7% had fibrosarcoma and 5% had angiosarcoma (Fig. 4). The mean size of

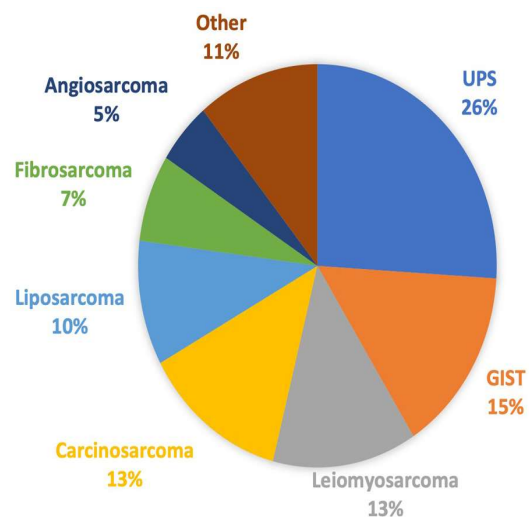


**Figure 2.** Distribution of patients by age

tumors with an interquartile range 9.75 cm ± 11.9 according to the histopathological evaluation (Fig. 5). In terms of the surgical intervention performed, 27 patients (71%) underwent R0 resection, 7 patients (18%) underwent R1 resection and 4 patients (10%) underwent R2 resection. In terms of additional organ resection, the following were performed small intestine resection in 15 patients (39%), colon resection in 11 patients (28%), stomach resection in 7 patients (18%), spleen resection in 7 patients (18%), liver resection in 5 patients



**Figure 3.** Age distribution of patients by gender



**Figure 4.** Histopathological classification of subjects

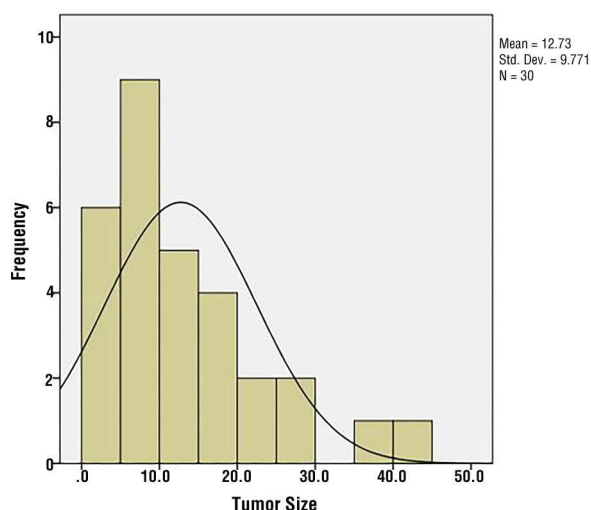


Figure 5. Distribution of tumor size

(13%) and bladder resection in 5 patients (13%). Also, peritoneum resection in 20 cases (52%) and pelvic lymph node dissection in 11 cases (28%) were performed. Organ resections performed are described in *Fig. 6*. One of the 2 patients with angiosarcoma had a tumor located between the vena cava and hepatic veins on suprarenal level, the other patient had a vena cava angiosarcoma with right renal vein involvement. Both patients underwent vena cava resection and vena cava reconstruction with vascular graft. The medical treatment of the third patient who was diagnosed with cardiac metastasis following the cardiac MRI is ongoing. Also, 6 patients were diagnosed with sarcomatosis and subsequently treated with cytoreductive surgery together with HIPEC.

Four (4) cases (10%) died on the first 30 days. The causes of mortality were of cardiac origin in 2 cases, pulmonary embolism in one case and sepsis in one case. Apart from this, the morbidity rate was 44% (17 subjects) and the most common cause of morbidity was reported as surgical site infection. Other morbidities observed were: anastomosis leaks, evisceration, intra-abdominal hematoma, acute kidney failure in the postoperative period and adrenal insufficiency which are discussed in *Table 2*.

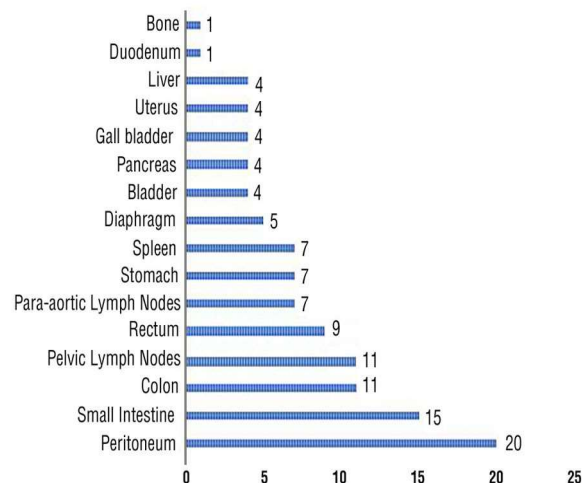


Figure 6. Additional organ resections

The mean follow-up duration of the cases was 18.25 months  $\pm$  10.03. According to the estimates of Kaplan-Meier survival analysis, the median overall survival was found to be 52.23  $\pm$  32.93 months. The 6-months, 1-year and 3-years survival rates were found to be 78%, 72% and 41%, respectively (*Table 3, Fig. 7*).

## Discussion

Mesenchymal cells, which form the basis of human body, form the supportive tissue by differentiating during embryonic period. Tumors with mesenchymal origin are derived

Table 2. Per-operative and first-30-days morbidity

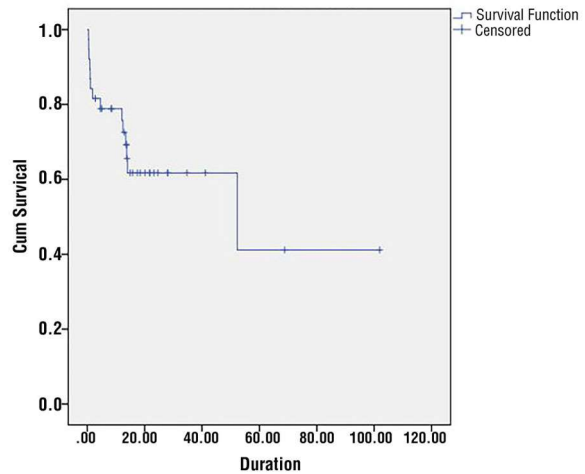
Per-op Morbidity	n (%)
Premature termination of surgery due to hemodynamic instability	2
Bilateral ureter damage	1
Bladder damage	1
Renal artery damage	1
Total	5 (13%)
First-30-days Morbidity	n (%)
Wound-site infection	6 (15%)
Anastomotic leak	3
Evisceration	1
Intra-abdominal hematoma	1
Adrenal Insufficiency	1
AKF	1
Post-op MI	1
Total	14 (39%)

**Table 3.** Survival analysis of patients who underwent abdominopelvic sarcoma resection

Overall	Median			
	Median Survival Months (95% CI)	6-months	1-y	3-y
52.23	78	72	41	

from muscle, adipose tissue, etc. which can be found in the entire human body (7). These tumors might be benign, however some are classified under the sarcoma title due to their aggressive behavior. More than half of the soft tissue sarcomas, which constitute only 1% of adult solid tumors, are localized on the extremities. Abdominopelvic localization is around 12% and the incidence is reported as 5 in 100000. It is twice as common in males as in females. During childhood they are generally seen as a part of genetic disorders such as Li Fraumeni syndrome, while in adulthood they are generally seen at the ages of 40 to 60 (3,8,9). These data are obtained from the United States and European countries and in Turkey to date, such a wide range of case series have not been found in the literature.

In this study, we have analyzed and presented the clinical, surgical treatment and early-stage outcomes of abdominally and retroperitoneally located sarcomas with mesenchymal origin. The demographic results differed in our study in terms of gender which was considered to be due to the presence of a high-volume gynecology department where a rather significant number of female patients from other clinics are referred to, while the mean age of patients in each gender remained similar compared to the literature. Additionally, this study includes vascular originated sarcomas and CRS-HIPEC cases which has been introduced as a new course of treatment of sarcomatosis in recent years. Histopathological evaluation demonstrated the mean tumor size to be 13 cm which was somewhat larger when compared to the data from previous studies (10). In terms of resection completeness, in our series R0 resection was achieved in 27 (71%) patients. With regards to post-operative complications, early-stage complications were somewhat higher in patients who underwent



**Figure 7.** Survival curves of subjects who underwent surgical operation

major organ resection and in recurrent cases. In terms of localization, abdominopelvic sarcomas are classified as retroperitoneal sarcomas and sarcomas originating from abdominal wall, pelvis and intra-abdominal organs (5). Due to the high degree of fatty tissue found in the retroperitoneal region, liposarcoma is found to be the most common tumor in this region, and leiomyosarcoma, liposarcoma and GIST are the most common group of tumors found in the abdomen and pelvis (3). In our study, histopathologically, undifferentiated sarcoma has been the most common tumor which was followed by GIST and leiomyosarcoma.

The new classification proposed by the World Health Organization in 2013, which brought significant changes to the previous classifications is still accepted today, although debates are still going on regarding the classification of sarcomas. Apart from the histopathological characteristics of the lesion, biological behaviors have been blended with the novel genetic findings in this new classification and different morphological types have been included. Additionally, the molecular structure of the tumor has been evaluated in more detail and has been an indicator for the treatment of the disease. The most important development in this field has been in gastrointestinal stromal tumors. The GIST group,

which was previously included in the gastrointestinal system tumors, was included in the soft tissue tumors group by WHO in 2013. Another modification in the GIST group has been described in the aggressive GIST subgroup which is accompanied by succinate dehydrogenase deficiency. GIST with enzyme deficiency can also form the third component of pheochromocytoma and pulmonary chondroma, creating Carney triad, or Carney-Stratakis syndrome only by accompanying paraganglioma. Such conditions may require genetic evaluation. Apart from this, changes were made in Ewing sarcoma and liposarcomas, and finally Undifferentiated/Unclassified Sarcomas have been included in the classification. This new classification is shown in *Fig. 1* (1,6,11)

Clinically, nearly half of the sarcomas are seen in the extremities. In terms of frequency, lower extremities seem to be affected more. According to the current literature, sarcomas located in the extremities are reported to have a better prognosis than those that are located in the abdomen. The reasons for this situation in the literature are listed as: difficulty in obtaining negative surgical margins, invasion of major vascular structures at the time of diagnosis, size of the mass, high grade, potential for metastasis, restrictions in chemo-radiotherapy (12,13). However, while sarcomas in the extremities present with clinical symptoms earlier, another reason for poor prognosis might also be related to the fact that other than those that are detected incidentally, abdominally located sarcomas are not possible to be diagnosed until they become symptomatic.

Because the tumor has an asymptomatic course until it becomes a large mass, most of the patients present with large tumors at the time of diagnosis. In a study conducted by Lewis JJ et al. on 500 patients with retroperitoneal sarcoma, only 6% of the cases had a tumor smaller than 5 cm, while 60% of the cases were reported to have tumors greater than 10 cm (6). Apart from incidental detection, gastrointestinal symptoms such as pain, neurological manifestations, early

satiety, nausea, vomiting, and ileus secondary to obstruction may occur as the tumor becomes larger or due to signs of pressure.<sup>14</sup> For intraabdominally located tumors, all abnormal findings must be evaluated with suspicion until proven otherwise. Due to the unique symptoms of gastrointestinal, gynecological and urinary system carcinomas, endoscopy can be performed for diagnosis and a biopsy can be obtained for confirmation. Since no such concern is present in solid tumors, radiological methods stand out in diagnosing sarcomas.

Radiologically, computed tomography and magnetic resonance imaging (MRI) are used for the diagnosis of tumors with abdominal mesenchymal origin. For staging, in line with the recommendations from the guidelines, organ-specific methods are being used for detection of metastasis. Currently, NCCN guidelines recommend Thoracic and Abdominopelvic CT together with abdominopelvic MRI (3,15,16). Tissue biopsy is only recommended for adjuvant chemotherapy in cases with unresectable or metastatic disease unamenable to surgery. A radiologist who is experienced both in abdominal radiology and sarcomas may help to establish the diagnosis and can also make a significant contribution to the planning of treatment and surgical strategy on vital tissues.

Another discussion regarding this matter is the use of PET-CT. In general, since sarcomas have high F-18-fluorodeoxyglucose (FDG) affinity, it can be used for initial diagnosis, staging, restaging, grading, evaluation of treatment response and radiation therapy planning. The advantages of PET/CT have been shown in distinguishing between changes secondary to radiation therapy and recurrences. In this context, guidelines recommend the use of PET/CT for patients who are planned to be treated with neoadjuvant therapy for Stage 2-3 disease of the extremities. However, F-18 FDG PET/CT cannot provide precise benign-malignant distinction in abdominal sarcomas, it can only help differentiate low grade tumors from high grade tumors with increased F-18 FDG uptake (17).

Hence, currently, there is a lack of strong evidence regarding the use of PET/CT in abdominal sarcomas and guidelines do not recommend its routine use. According to the study conducted by Dao-ning Liu et al. in this regard, PET-CT findings of 195 sarcoma cases did not yield positive results in terms of benign/malignant distinction, while statistically significant results were obtained in terms of Ki 67 and mitotic index (18). Consequently, we believe that new large-scale studies which contain histopathological subgroups are needed.

Nowadays, substantial improvements have been achieved in medical oncology and radiation oncology fields. However, except for GISTs, positive results still cannot be achieved with chemotherapy or radiation therapy in sarcomas with abdominal localization. In unresectable or metastatic sarcomas, combined therapies with doxorubicin or gemcitabine or single-agent treatment regimens can be administered. Similarly, based on the tolerability of the tissue, radiation therapy up to 50 Gy may be applied. Post-operative treatment regimens can be selected according to the status and the subtype of the tumor (19,20). Another development in recent years is immunotherapy. However, there are no current suggestions with a high level of evidence in this regard.

The most important step of treatment in sarcomas is the resection of tumors with adequate surgical margins and in recent years successful results have been reported from various centers. When these results are evaluated, it can be observed that the histopathological and tumor-related characteristics of asymptomatic sarcomas and sarcomas growing with an insidious clinical pattern are similar to those reported in previous years. In terms of long-term survival, en block resection with negative surgical margins is the principle corner stone for the management of the disease. Previously, sarcomas with large vessel invasion or close involvement with anatomically vital organs were deemed to be inoperable or related to high early recurrence rates due to inadequate resections. Today, even vena cava originated angiosarcomas can be resected with vascular

reconstruction with satisfying results. Studies highlighting the importance of experience and multidisciplinary work can be found in the literature (21). The first of these was the Scandinavian Sarcoma Study Group in 1979, and in subsequent years consensus decisions were taken to establish centers particularly for collecting reliable data related to sarcoma. Finally, NICE (National Institute Health and Care) group has determined the prerequisites for centers in which sarcoma can be treated (22). In our department, based on these recommendations of NICE, all the data have been recorded in a template and the treatment of abdominal solid tumor cases are managed in a multidisciplinary approach accordingly.

Another development in this area has been cytoreductive surgery and HIPEC application. For HIPEC following CRS, which has become popular in recent years, indications have been reported by Sugarbaker as cases with low-volume residual tumors, tumor perforation, recurrence and seeding of the tumor. In this practice, following adequate resection, doxorubicin together with ifosfamide or doxorubicin together with mitomycin regimens are used in the centers (5,23,24). General information regarding this subject were summarized in a review prepared by Sugarbaker in 2004. After this, limited number of studies in nature of case series have been published to date. Among these studies, Sugarbaker et al. reported up to 58 months of disease free survival following CRS and HIPEC in 2 patients with abdominal sarcomatosis (25). In another study, adequate CRS was reported to be the standard of care and that the effect of HIPEC application was not clearly understood (26). In the study conducted by Bonvolat et al., cytoreductive surgery alone was compared with cytoreductive surgery applied concurrently with HIPEC. This study is one of the rare prospective, randomized studies and no difference has been shown between the two groups in terms of disease-free survival and overall survival (27). New, multicenter, randomized controlled trials are required in this field.

In our study, 6 subjects with sarcomatosis

were treated with CRS together with HIPEC and none of the subjects presented with drug-induced toxicity and 2 subjects developed surgical site infection, which was controlled with local wound care. In this group of patients, no mortality occurred during hospital stay, and none of these patients developed recurrence by the end of 6 months. We are planning another study to be published in the future which will consist of our results following increasing number of subjects.

## Conclusion

Tumors with mesenchymal origin located in the abdominopelvic area are rare. In this study, we present the demographics and clinical results of 38 patients from our tertiary center. One of the advantages of this study is the prospective recording of all patient data starting from the first patient and bringing these data into the literature. Our cases include major vascular resections performed for vena cava angiosarcoma, which are rare in published literature. The most important stage in this endeavor, which started about 3 years ago, is the creation of a multidisciplinary team in which all the necessary specialties were included. Surgical interventions and major organ resections were discussed case by case in the board with the inclusion of corresponding specialties such as urology. Also, cytoreductive surgery together with HIPEC application in patients with sarcomatosis which became a popular approach in the 90s was also applied to our patients when indicated.

At this point, surgical approach made it possible to gain experience starting from the first case, enabled challenging resections in due time and contemporary treatment strategies have been performed in the light of the guidelines. As of 2019, NICE recommendations were followed and fully implemented.

In conclusion, surgery is the gold standard treatment of abdominopelvic and retroperitoneal sarcomas. Since these malignancies require complex surgical interventions, we

believe that the treatment and management of these tumors should be performed with a multidisciplinary approach in centers experienced in these conditions.

## Conflict of Interest

The author(s) have no potential conflicts of interest to declare.

## Funding: None

## Ethics Approval

This study is ethically approved by the Ethics Committee of University of Health Sciences Umraniye Training and Research Hospital with the Reference Number: B.10.1.TKH. 4.34.H. GP.0.01/220.

## References

1. Marino-Enriquez A, Bovee JV. Molecular Pathogenesis and Diagnostic, Prognostic and Predictive Molecular Markers in Sarcoma. *Surg Pathol Clin*. 2016;9(3):457-73.
2. Helmlinger T. Mesenchymal abdominal tumors. *Radiologe*. 2018;58(1):1-2.
3. Levy AD, Manning MA, Al-Refaei WB, Miettinen MM. Soft-Tissue Sarcomas of the Abdomen and Pelvis: Radiologic-Pathologic Features, Part 1-Common Sarcomas: From the Radiologic Pathology Archives. *Radiographics*. 2017;37(2):462-83.
4. Sondak VK, Economou JS, Eilber FR. Soft tissue sarcomas of the extremity and retroperitoneum: advances in management. *Adv Surg*. 1991;24:333-59.
5. P. S. Management of Abdominopelvic Sarcoma. In: *Musculoskeletal Cancer Surgery*. In: Malawer MMeaE, editor. *Musculoskeletal Cancer Surgery*. Dordrecht: Springer; 2004. p. 147-63.
6. Doyle LA. Sarcoma classification: an update based on the 2013 World Health Organization Classification of Tumors of Soft Tissue and Bone. *Cancer*. 2014;120(12):1763-74.
7. Jimenez-Puerta GJ, Marchal JA, Lopez-Ruiz E, Galvez-Martin P. Role of Mesenchymal Stromal Cells as Therapeutic Agents: Potential Mechanisms of Action and Implications in Their Clinical Use. *J Clin Med*. 2020;9(2):445.
8. Levy AD, Manning MA, Miettinen MM. Soft-Tissue Sarcomas of the Abdomen and Pelvis: Radiologic-Pathologic Features, Part 2-Uncommon Sarcomas. *Radiographics*. 2017;37(3):797-812.
9. Peacock O, Patel S, Simpson JA, Walter CJ, Humes DJ. A systematic review of population-based studies examining outcomes in primary retroperitoneal sarcoma surgery. *Surg Oncol*. 2019;29:53-63.
10. Nishimura J, Morii E, Takahashi T, Souma Y, Nakajima K, Doki Y, et al. Abdominal soft tissue sarcoma: a multicenter retrospective study. *Int J Clin Oncol*. 2010;15(4):399-405.
11. Joensuu H, Hohenberger P, Corless CL. Gastrointestinal stromal tumour. *Lancet*. 2013;382(9896):973-83.
12. Wang WL. Prognostication in Mesenchymal Tumors: Can We Improve? *Surg Pathol Clin*. 2019;12(1):217-25.
13. Elkrief A, Alcindor T. Molecular targets and novel therapeutic avenues in soft-tissue sarcoma. *Curr Oncol*. 2020;27(Suppl 1):34-40.
14. Kirchberg J, Weitz J. [Intra-abdominal and retroperitoneal sarcomas]. *Chirurg*. 2016;87(3):255-66; quiz 67.
15. Messiou C, Moskovic E, Vanel D, Morosi C, Benchimol R, Strauss D, et al.

- Primary retroperitoneal soft tissue sarcoma: Imaging appearances, pitfalls and diagnostic algorithm. *Eur J Surg Oncol.* 2017;43(7):1191-8.
16. Zhang WD, Li CX, Liu QY, Hu YY, Cao Y, Huang JH. CT, MRI, and FDG-PET/CT imaging findings of abdominopelvic desmoplastic small round cell tumors: correlation with histopathologic findings. *Eur J Radiol.* 2011; 80(2):269-73.
  17. Hung TJ, McLean L, Mitchell C, Pascoe C, Lawrentschuk N, Murphy DG, et al. The role of (18)F-FDG-PET/CT in evaluating retroperitoneal masses - Keeping your eye on the ball! *Cancer Imaging.* 2019;19(1):28.
  18. Liu DN, Li ZW, Wang HY, Zhao M, Zhao W, Hao CY. Use of 18F-FDG-PET/CT for Retroperitoneal/Intra-Abdominal Soft Tissue Sarcomas. *Contrast Media Mol Imaging.* 2018;2018:2601281.
  19. Dangoor A, Seddon B, Gerrand C, Grimer R, Whelan J, Judson I. UK guidelines for the management of soft tissue sarcomas. *Clin Sarcoma Res.* 2016;6:20.
  20. Smith HG, Tzani D, Messiou C, Benson C, van der Hage JA, Fiore M, et al. The management of soft tissue tumours of the abdominal wall. *Eur J Surg Oncol.* 2017;43(9):1647-55.
  21. Sandrucci S, Trama A, Quagliuolo V, Gronchi A. Accreditation for centers of sarcoma surgery. *Updates Surg.* 2017;69(1):1-7.
  22. Benson C, Judson I. Role of expert centres in the management of sarcomas - a UK perspective. *Eur J Cancer.* 2014;50(11):1951-6.
  23. Piso P, Leebmann H, März L, Mayr M. [Cytoreductive surgery for malignant peritoneal tumors]. *Chirurg.* 2015;86(1):38-46.
  24. Colombo C, Baratti D, Kusamura S, Deraco M, Gronchi A. The role of hyperthermic intraperitoneal chemotherapy (HIPEC) and isolated perfusion (ILP) interventions in sarcoma. *J Surg Oncol.* 2015;111(5):570-9.
  25. Sugarbaker PH. Long-term survival is possible using cytoreductive surgery plus HIPEC for sarcomatosis-Case report of 2 patients. *Int J Surg Case Rep.* 2019;64:10-4.
  26. Randle RW, Swett KR, Shen P, Stewart JH, Levine EA, Votanopoulos KI. Cytoreductive surgery with hyperthermic intraperitoneal chemotherapy in peritoneal sarcomatosis. *Am Surg.* 2013;79(6):620-4.
  27. Bonvalot S, Cavalcanti A, Le Péchoux C, Terrier P, Vanel D, Blay JY, et al. Randomized trial of cytoreduction followed by intraperitoneal chemotherapy versus cytoreduction alone in patients with peritoneal sarcomatosis. *Eur J Surg Oncol.* 2005;31(8):917-23.