

The Impact of Temporal Variation in ICG Administration on Axillary Node Identification During Reverse Mapping Procedures

Mirela Mariana Roman¹, Jean-Marie Nogaret¹, Isabelle Veys¹, Pauline Delrue¹, Christine Eddy¹, Clarence Karler⁴, Véronique Del Marmol², Pierre Bourgeois^{2,3,5}

¹Department of Mammo-Pelvic Surgery, Institute Jules Bordet, Université Libre de Bruxelles, Brussels, Belgium

²Service of Dermatology, Hospital Erasme, Université Libre de Bruxelles, Brussels, Belgium

³Services of Nuclear Medicine, Institute Jules Bordet and HIS-IZZ Hospitals, Université Libre de Bruxelles, Brussels, Belgium

⁴Department of Anesthesia-Algology, Hospital Moliere, Université Libre de Bruxelles, Brussels, Belgium

⁵Service of Vascular Surgery, HIS-IZZ Hospitals, Université Libre de Bruxelles, Brussels, Belgium

*Corresponding author:
Mirela Mariana Roman, MD
Institute Jules Bordet
Rue Meylemeersch 90
1070 – Bruxelles
Tel: 003225413164
E-mail: mirela-mariana.roman@bordet.be

Rezumat

Impactul variației temporale în administrarea ICG asupra identificării nodului axilar în timpul procedurilor de cartografiere inversă

ICG împreună cu alți coloranți pot fi injectați pre și/sau per operator pentru a identifica ganglionii limfatici axilari (LN) care drenează cancerul de sân (ganglionul SLN) și/sau al brațului homolateral (ganglionii brațului).

Obiectivul: evaluarea impactului acestei variații temporale asupra identificării acestor ganglioni ai brațului.

Materiale și Metode: O sută nouă femei, care au fost programate să beneficieze de lumpectomie cu limfadenectomie selectivă (SLN) sau fie lumpectomie, fie mastectomie cu disecție completă a ganglionilor limfatici axilari (CALND) pentru un cancer dovedit histologic, au primit cu o zi înainte de intervenția chirurgicală o injecție subcutanată de ICG în primul spațiu interdigital al mâinii homolaterale (subgrup pre-op (SLN=28 și CALND=15), sau în aceeași zi cu intervenția chirurgicală (subgrup per-op (SLN=26 și CALND= 20)). Caracteristicile fluorescente al ganglionului SLN și/sau al ganglionilor limfatici axilari au fost analizate și comparate între cele două subgrupuri.

Resultate: Caracteristicile de bază nu au fost semnificativ diferite între subgrupurile pre și per op. Procentul de pacienți cu SLN fluorescent (28%), procentul de pacienți cu ganglioni limfatici axilari fluorescent în CALND (74.5%) sau procentul de ganglioni limfatici fluorescent în CALND (38.5%) nu a fost de

Received: 04.04.2022
Accepted: 06.06.2022

asemenea semnificativ.

Concluzie: Injectarea ICG în primul spațiu interdigital al mâinii homolaterale efectuată cu o zi înainte de operație sau în aceeași zi cu operația nu are nicio influență semnificativă în studiul nostru la detectarea ganglionilor axilari limfatici ai brațului. Timpul injectării ICG este o variabilă independentă fără efect pe rezultate; acest lucru permite ca injectarea să fie efectuată fie cu o zi înainte de operație, fie în aceeași zi cu chirurgia.

Cuvinte cheie: ICG, timp, ganglioni, cancer, sân

Abstract

ICG with other tracers can be injected pre and/or per operatively to identify the axillary Lymph Nodes (LN) draining the breast cancer (the SLN nodes) and/or the ipsilateral arm (the ARM nodes).

Objective: to evaluate the impact on this temporal variable-variation on the identification of these ARM LN.

Material and methods: One hundred and nine women, who were scheduled to undergo, either lumpectomy with selective lymphadenectomy (SLN), or mammary surgery (either lumpectomy, or mastectomy) with complete axillary node dissection (CALND) for a histologically proven mammary tumor, had administered the day before the surgery one subcutaneous injection of ICG in the first interdigital space of the ipsilateral hand (pre-op subgroup (SLN=28 and CALND=15), or the same day as the surgery (per op subgroup (SLN=26 and CALND= 20). The fluorescent characteristics of the SLN and/or axillary LN were then analyzed and compared between the two subgroups.

Results: Basic characteristics were not significantly different between the pre and per op subgroups. The percentage of patients found with fluorescent SLN (28%), the percentage of patients with fluorescent LN in CALND (74.5%), or the percentage of LN fluorescent in CALND (38.5%) did not differ significantly too.

Conclusion: Injection of ICG in the first interdigital space of the hand of operated side performed one day before the surgery or the same day as the surgery has no significant influence in our study on detection of the arm nodes. The timing of ICG injection is an independent variable with no effect on the results; this allows the injection to be performed either the day before the surgery or the day of the surgery.

Key words: ICG, time, lymph node, cancer, breast

Introduction

Axillary lymph node surgery is essential for the treatment of breast cancer but can cause morbidities.

Sentinel lymph node biopsy (SLNB) has become an alternative procedure to complete axillary lymph node dissection (CALND) with a lower risk of significant operative morbidity and now is the gold standard procedure in early breast cancer, avoiding the complications of CALND (1).

Among various tracers for SLNB, indocyanine green (ICG) is used to detect these nodes in patients with breast cancer surgery (2-4).

But the use of ICG injection has also been proposed for the Axillary Reverse Mapping (ARM) approach. This novel surgical technique aims to distinguish the lymphatic drainage pattern of the upper limb from that of the breast, to preserve arm lymphatic drainage and to decrease complications seen after axillary lymph node dissection for patients with breast cancer surgery (5-7). For

instance, this technique has been shown its potential to decrease the frequency of upper limb lymphedema (ULLE) (7-10).

The tracers can be and were injected pre-operatively before breast surgery (10) or per-operatively after general anaesthesia induction (11-15) raising the question of the impact on this temporal variable-variation on the identification of the ARM lymph node (LN).

The aim of our study was to evaluate whether the pre-op or per-operative injection of ICG led to different results in the distribution of the tracer of the sentinel and/or axillary LN of patients with breast cancer.

Material and Methods

This prospective monocentric study was approved by the Investigational Review Board (IRB) of the Jules Bordet Institute (CE2876) and was registered at the European Clinical Trials Database (EudraCT number 2018-002862-38).

Between June 2019 and June 2021, we successively enrolled in the study after providing written informed consent (see *Fig. 1*) one hundred and nine women (mean age = 61, range 23-93 years) who were scheduled to undergo, either lumpectomy (n=54) with selective lymphadenectomy (SLN) (mean age= 62,1 range 28-93 years), or mastectomy (n = 20) with complete axillary node dissection or lumpectomy (n=35) (mean age 59,9, range 23-89 years) with complete axillary node dissection (CALND) for a histologically proven mammary tumor. These minimal numbers were “a priori” calculated by our statistician (MP).

Exclusion criteria were: (1) History of iodine allergy or anaphylactic reactions to insect bites or medication; (2) Hyperthyroidism; (3) Severe cardiac or pulmonary disease; (4) Significant renal failure (creatinine > 400 $\mu\text{mol/l}$); (4) Pregnancy. Patients were not limited in their normal behavior, diet, or medication intake before the study.

ICG (0.2 ml from 25 mg of ICG diluted by 5.0 ml of aqua distillate) was injected subcutaneous in the first interdigital space of the hand on the surgery side, either the day before the surgery, or the same day as the surgery (at the induction of anesthesia or within the half hour before), depending on the patient's hospitalization time.

For the SLNB identification, radio-colloids were injected in the breast and around the tumor the day before surgery and before the injection of ICG. The sentinel and all the LN seen on pre-operative lymphoscintigram with a signal higher than 10% of the most active one (16) were removed in the surgical room.

For the patients who underwent a standard CALND, at least level I-II lymph nodes were removed.

Fluorescent nodes, considered as ARM nodes, were identified in the surgical room using our near infra-red camera system (PDE, Hamamatsu) and sent separately to pathology.

Thus, the outcomes were defined as the potential differences between pre and per operative injection (of ICG in the ipsilateral limb) on the fluorescence or not of axillary LN (SLNB in case of selective lymphadenectomy and/or axillary nodes found in case of CALND).

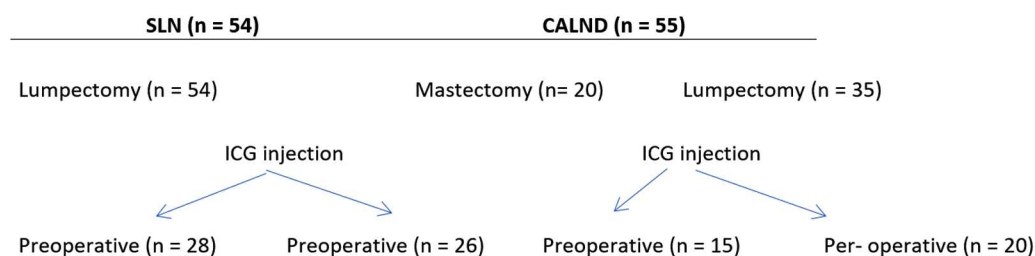


Figure 1. Enrolment

Statistical Analysis

Our analysis is based on a set of statistical tests to assess the impact of the temporal variation in ICG administration on the main parameters. The parameters of interest were studied as different categories of variables (fluorescence or not of the SLNB, fluorescence or not of the axillary LN in the CALND, pN+ status) and as quantitative variables (number/percentage of fluorescent lymph nodes in the CALND). The standard chi-square test was used to assess whether the parameters of interest depend on the timing of ICG injection. However, when the number of patients for a given category is too small, the Fisher exact test was used. On the other hand, the Kruskal-Wallis non-parametric test was used to determine if the distributions of the quantitative variables are different depending on the moment of the ICG injection. A nonparametric method was applied when the Shapiro-Wilk test led to the rejection of the normality hypothesis. All statistical analyses were carried out using the R software. We consider 0.05 as the level of significance for all statistical tests (17).

Results

The characteristics of patients are shown in *Table 1*. The SLNB patients in group A (pre-operative injected) show no statistically differences from the patients in group C (per-operative injected) as well as CALND patients in group B (pre-operative injected) from the ones in group D (per-operative injected).

As shown in *Table 2*

- In the whole SLNB group, 28% of the patients (15/54) had their SLN fluo and the percentages were not significantly different in the pre-operative (23%) and post-operative (32%) injected sub-groups.
- In the whole CALND group, 74.5% of the patients (41/55) had ax LN fluo and the percentages were identical in the pre-operative (73%) and post-operative (76%) injected sub-groups. The mean numbers

of fluo axillary LN (4.23) and the mean percentages of LN found fluo (38-39%) related to the total number of ax LN in the axillary piece of dissection were also identical for both sub-groups.

- Most important, even if 36/55 (66%) of the patients were pN+ in the whole CALND group, the percentages of pN+ patients with axillary LN also found fluo were similar in the pre and per op sub-groups (27-28%).

Discussion

Post-operative complications are frequent in the patients treated for Breast Cancer (BC). Upper Limb Lymphedemas (ULLE)(18,19), axillary web syndrome (AWS) (20-22), axillary infection (AxI) (23), seromas (24) are respectively reported ranging from 6 % to 77% for ULLE (18,19,25,26), from 6 % to 86% for AWS (20,21,22,27), from 3% to 15 % for AxI infection (23,28) and from 10 % to 50% for seroma (24,29-32).

ARM was proposed in 2007 (5) to preserve the upper extremity lymphatic drainage system during SLNB and/or CALND and to avoid the complications of these surgeries and the technique is now performed in some centers in the world.

The ARM techniques can be performed by using blue dye (5,12-15), radio-colloids (15,33) fluorescent dyes such as ICG (34,35) or combined method (blue dye and radio-colloids) (36). However, injections for visualisation of ARM nodes are reported in the literature with variables pre-operative times (10,12-15).

In this study, injection of ICG subcutaneous in the first interdigital space of the hand of operated side, either the day before the surgery, or the same day as the surgery has no significant influence on the percentage of patients found with fluorescent SLN (23-32%), on the percentage of patients with fluorescent lymph nodes in their CALND (73-76%) or on the percentage of fluorescent lymph nodes in these CALND (39-37%).

Most of the authors reporting on ARM results are performing their per-operative

Table 1. Characteristics of patients

	Preoperative injection of ICG			Per operative injection of ICG		
	SLNB(A)	CALND(B)	SLNB©	CALND(D)	A vs C	B vs d
No. patients	28	26	26	29	p	P
Age						
Median	60,7	58,9	63,5	60,9	ns	ns
Range	28-83	39-89	35-93	23-85		
BMI						
Median	27,1	28,5	26,2	27,5	ns	ns
Range	19,8-40	17,4-41	18,5-40,2	18,6-41		
Lateralization						
Left	13	17	16	17	ns	ns
Right	15	9	10	12		
Tumor size, mm						
Median	17,14	34,2	18	33,72	ns	ns
Range	avr-70	10-70	8 -30	8-87		
Histology						
IDC	25	21	25	27	ns	ns
ILC	3	5	1	2		
Molecular classification						
Luminal A	7	2	1	0		
Luminal B	15	15	18	13		
HER2-enriched	1	1	1	9		
Triple negative	5	6	6	7	ns	ns
Grade						
3	7	10	12	16		
2	13	12	6	12	ns	ns
1	8	4	8	1		
No. of lymph node resected						
CALND						
Median		9.8		11.1		ns
Range		4 -29		5-27		
No. of lymph node resected						
SLNB						
Median	1,89		2,08			ns
Range						
Axillary status						
pN0	27	11	24	8		
pN+	1	15	2	21	ns	ns
Type of surgery						
Lumpectomy	28	15	26	20		
Mastectomy	0	11	0	9		ns

ICG, indocyanine green; SLNB, sentinel lymph node biopsy; CALND, complete axillary lymph node dissection; BMI, body mass index; IDC, invasive ductal carcinoma; ILC, invasive lobular carcinoma

Table 2. Patient Sub-groups with fluorescence axillary lymph nodes

	ICG injection		
	Pre-operative	Per-operative	
SLN Sub-Groups			
Patients with SLN Fluo	6/26 (23%)	9/28 (32%)	NS
pN+ patients with SLN Fluo	0/1	0/2	NS
CALND Sub-Groups			
Patients with AxLN Fluo	19/26 (73%)	22/29 (76%)	NS
Patients with pN+ AxLN Fluo	4/26 (15%)	6/29 (20%)	NS
pN+ patients with pN+ LN Fluo	4/15 (27%)	6/21 (28%)	NS
Numbers of AxLN Fluo			
Mean	4.23	4.23	NS
Range	0-17	0-14	
Percentages of AxLN Fluo ¹	39.3	37.8	NS

¹Percentages of AxLN Fluo means: mean of the observed values in the numbers of LN fluo per total number of LN found in the axillary piece of dissection; SLN, sentinel lymph node; AxLN Fluo, axillary lymph node fluorescent; CALND, complete axillary lymph node dissection;

injection but they differ in terms of the used tracer and the injection site (37). With ICG injected in the inner site of the wrist (near the site chosen in our study), Noguchi et al (34) reported in their series (smaller than ours) the ARM nodes as fluorescent in 7 (88%) of 8 patients who underwent CALND (one result as ours). With ICG injected in the medial aspect of the proximal arm at the intermuscular groove, Xiaokai Ma et al (38) reported that the node identification rate using ARM was 95.7% (44 of 46 patients) in their CALND and their mean number of removed ARM-detected nodes was 4.1 (range, 1–12), the same mean number of fluo axillary LN as in our series with a range from 0 to 14.

For patients who underwent SLN biopsy, also with ICG injected in the inner site of the wrist, Noguchi et al (34) reported in their series the ARM nodes as fluorescent in 9 (75%) of 12. On the other hand, also with ICG in the medial aspect of the proximal arm at the intermuscular groove, Foster et al (35) reported that 8 out of 20 patients (40%) had the SLN fluorescent, one percentage more similar to ours.

The oncological safety of ARM becomes more as an issue in the area were crossover nodes between the arm and breast lymphatics may be found in the axilla and can provide a route for metastatic cancer cells to spread (39,40).

SLNB is recommended and performed in women with clinically node-negative early breast cancer (41). However, previous studies reported that the crossover rates between SLNs and ARM nodes ranged from 2.2 to 28.0% (12,44) with ARM nodes being pN+ in 0 % to 32 % (5,42). We observed in the SLNB group the same high percentages of crossover (27.5%) as Noguchi et al (42) but the percentages were not significantly different in the pre-operative (23%) and post-operative (32%) injected sub-groups and no patient had their SLN fluo pN+.

For cN+ patients, standard ALND remains the treatment of choice because metastatic rate of ARM nodes is high in cN+ patients, ranging from 16.5 % to 36.8 % in the literature (43). In

our series, the percentages were not significantly different in the pre-operative (15%) and post-operative (20%) injected sub-groups.

Conclusion

It is concluded that injection of ICG subcutaneously in the first interdigital space of the hand of operated side before or on the same day has no significant influence in our study on the percentage of patients found with fluorescent SLNB, the percentage of patients with fluorescent lymph nodes in CALND, or the percentage of lymph node fluorescent in CALND. In practice this means that this injection of ICG for the arm nodes can be done either the day before the surgery or on the same day as the surgery, as it is for the SLN identification with colloids.

Conflict of Interest

The authors declare no conflicts of interests.

References

1. Lyman GH, Temin S, Edge SB, Newman LA, Turner RR, Weaver DL, et al. Sentinel lymph node biopsy for patients with early-stage breast cancer: American Society of Clinical Oncology clinical practice guideline update. *J Clin Oncol*. 2014;32(13):1365-83.
2. Aoyama K, Kamio T, Ohchi T, Nishizawa M, Kameoka S. Sentinel lymph node biopsy for breast cancer patients using fluorescence navigation with indocyanine green. *World J Surg Oncol*. 2011;9:157-157.
3. Liu J, Huang L, Wang N, Chen P. Indocyanine green detects sentinel lymph nodes in early breast cancer. *J Int Med Res*. 2017;45(2): 514-524.
4. Rui Yin, Lu-Yu Ding, Qing-Zhong Wei, Ya Zhou, Guang-Yuan Tang, Xun Zhu Comparisons. *Oncol Lett*. 2021;21(2):114.
5. Thompson M, Korourian S, Henry-Tillman R, Adkins L, Mumford S, Westbrook KC, et al. Axillary reverse mapping (ARM): a new concept to identify and enhance lymphatic preservation. *Ann Surg Oncol*. 2007;14(6): 1890-5.
6. Noguchi M. Axillary reverse mapping for breast cancer. *Breast Cancer Res Treat*. 2010;119(3):529-35.
7. Noguchi M. Axillary reverse mapping for preventing lymphedema in the axillary lymph node dissection and/or sentinel lymph node biopsy. *Breast Cancer*. 2010;17(3):155-7. Epub 2009 Sep 30.
8. Yue T, Zhuang D, Zhou P, Zheng L, Fan Z, Zhu J, et al. A prospective study to assess the feasibility of axillary reverse mapping and evaluate its effect on preventing lymphedema in breast cancer patients. *Clin Breast Cancer*. 2015;15(4):301-6.
9. Ikeda K, Ogawa Y, Kajino C, Deguchi S, Kurihara S, Tashima T, et al. The influence of axillary reverse mapping related factors on lymphedema in breast cancer patients. *Eur J Surg Oncol*. 2014;40(7):818-23.
10. Gennaro M, Maccauro M, Sigari C, Casalini P, Bedodi L, Conti AR, et al. Selective axillary dissection after axillary reverse mapping to prevent breast-cancer-related lymphoedema. *Eur J Surg Oncol*. 2013;39(12):1341-5.
11. Pavlista D, Eliška O. Analysis of direct oil contrast lymphography of upper limb lymphatics traversing the axilla -- a lesson from the past -- contribu-

- tion to the concept of axillary reverse mapping. *Eur J Surg Oncol*. 2012; 38(5):390-4.
12. Boneti C, Korourian S, Bland K, Cox K, Adkins LL, Henry-Tillman RS, et al. Axillary reverse mapping: mapping and preserving arm lymphatics may be important in preventing lymphedema during sentinel lymph node biopsy. *J Am Coll Surg*. 2008;206(5):1038-42; discussion 1042-4.
 13. Casabona F, Bogliolo S, Valenzano M, Sala P, Villa G, Ferrero S. Feasibility of axillary reverse mapping during sentinel lymph node biopsy in breast cancer patients. *Ann Surg Oncol*. 2009;16(9):2459-63.
 14. Ponzone R, Mininanni P, Cassina E. Axillary reverse mapping in breast cancer: can we spare what we find? *Ann Surg Oncol* 2008;15:390-1.
 15. Nos C, Kaufmann G, Clough KB, Collignon MA, Zerbib E, Cusumano P, et al. Combined axillary mapping (ARM) technique for breast cancer patients requiring axillary dissection. *Ann Surg Oncol*. 2008;15:2550-2555.
 16. Martin RC 2nd, Edwards MJ, Wong SL, Tuttle TM, Carlson DJ, Brown CM, et al. Practical guidelines for optimal gamma probe detection of sentinel lymph nodes in breast cancer: results of a multi-institutional study. For the University of Louisville Breast Cancer Study Group. *Surgery*. 2000;128(2): 139-44.
 17. Lalanne C, Mesbah M. Measures of Association, Comparisons of Means and Proportions for Two Samples or More. 2016. 10.1016/B978-1-78548-142-0.50002-X.
 18. Petrek JA, Heelan MC. Incidence of breast carcinoma-related lymphedema. *Cancer* 1998;83:2776-81.
 19. Petrek JA, Senie R.T, Peters M, Rosen PP. Lymphedema in a cohort of breast carcinoma survivors 20 years after diagnosis. *Cancer*. 2001;92(6): 1368-77.
 20. Leidenius M, Leppänen E, Krogerus L, von Smitten K. Motion restriction and axillary web syndrome after sentinel node biopsy and axillary clearance in breast cancer. *Am J Surg*. 2003;185(2):127-130.
 21. O'Toole J, Miller CL, Specht MC, Skolny MN, Jammallo LS, Horick N, et al. Cording following treatment for breast cancer. *Breast Cancer Res Treat*. 2013;140(1):105-11.
 22. Bergmann A, Mendes VV, de Almeida Dias R, do Amaral E Silva B, da Costa Leite Ferreira MG, Fabro EA. Incidence and risk factors for axillary web syndrome after breast cancer surgery. *Breast Cancer Res Treat*. 2012; 131(3): 987-992.
 23. Lefebvre D, Penel N, Deberles MF, Fournier C. Incidence and surgical wound infection risk factors in breast cancer surgery. *Presse Medicale* 2000;29(35):1927-32.
 24. Roman M, Nogaret JM, Fils JF, Bourgeois P. Seromas and punctures after complete axillary node dissection for breast cancer: differences between mastectomy and lumpectomy. *J Surg*. 2015;3(2):7.
 25. Nesvold IL, Reinertsen KV, Fosst SD, Dahl AA. The relation between arm/shoulder problems and quality of life in breast cancer survivors: a cross-sectional and longitudinal study. *J Cancer Surviv*. 2011;5(1):62-72.
 26. Suami H, Chang DW. Overview of surgical treatments for breast cancer-related lymphedema. *Plast Reconstr Surg*. 2010;126(6):1853-1863.
 27. Koehler LA, Blaes AH, Haddad TC, Hunter DW, Hirsch AT, Ludewig PM. Research report movement, function, pain, and postoperative edema in axillary web syndrome. *Phys Ther*. 2015;95(10):1345-1353.
 28. Witt A, Yavuz D, Walchetseder C, Strohmer H, Kubista E. Preoperative core needle biopsy as an independent riskfactor for wound infection after breast surgery. *Obstet Gynecol*. 2003;101(4):745-50.
 29. Lumachi F, Brandes AA, Burelli P, Basso SM, Iacobone M, Ermani M. Seroma prevention following axillary dissection in patients with breast cancer by using ultrasound scissors: a prospective clinical study. *Eur J Surg Oncol*. 2004;30(5):526-30.
 30. Vinton AL, Traverso LW, Jolly PC. Wound complications after modified radical mastectomy compared with tylectomy with axillary lymph node dissection. *Am J Surg*. 1991;161(5):584-8.
 31. Burak WE Jr, Goodman PS, Young DC, Farrar WB. Seroma formation following axillary dissection for breast cancer: risk factors and lack of influence of bovine thrombin. *J Surg Oncol*. 1997;64(1):27-31.
 32. Tejler G, Aspegren K. Complications and hospital stay after surgery for breast cancer: a prospective study of 385 patients. *Br J Surg*. 1985;72(7): 542-4.
 33. Britton TB, Solanki CK, Pinder SE, Mortimer PS, Peters AM, Purushotham AD. Lymphatic drainage pathways of the breast and the upper limb. *Nucl Med Commun*. 2009;30(6):427-30.
 34. Noguchi M, Yokoi M, Nakano Y. Axillary reverse mapping with indocyanine fluorescence imaging in patients with breast cancer. *J Surg Oncol*. 2010; 101(3):217-21.
 35. Deshka Foster, Nicole Choy, Catherine Porter, Shushmita Ahmed, Irene Wapnir. Axillary reverse mapping with indocyanine green or isosulfan blue demonstrate similar crossover rates to radiotracer identified sentinel nodes. *J Surg Oncol*. 2018 Mar; 117(3):336-340.
 36. Tausch C, Baege A, Dietrich D, Vergin I, Heuer H, Haldemann Heusler R, et al. Can axillary reverse mapping avoid lymphedema in node positive breast cancer patients? *Eur J Surg Oncol*. 2013;39(8):880-6.
 37. Wu JD, Wang Z, Zeng HC, He LF, Zhang YQ, Huang GS, et al. Comparison of indocyanine green and methylene blue use for axillary reverse mapping during axillary lymph node dissection. *MedComm*. 2020;1(2):211-218.
 38. Xiaokai Ma, Shishuai W, Baofeng L, Dumin L, Xiaolong W, Xiaoli K et al. Relationship between upper extremity lymphatic drainage and sentinel lymph nodes in patients with breast cancer. *J Oncol*. 2019;2019:8637895.
 39. Ashikaga T, Krag DN, Land SR, Julian TB, Anderson SJ, Brown AM, et al. National Surgical Adjuvant Breast, Bowel Project. Morbidity results from the NSABP B-32 trial comparing sentinel lymph node dissection versus axillary dissection. *J Surg Oncol*. 2010 Aug 1;102(2):111-118.
 40. Lucci A, McCall LM, Beitsch PD, Whitworth PW, Reintgen DS, Blumencran PW. Surgical complications associated with sentinel lymph node dissection (SLND) plus axillary lymph node dissection compared with SLND alone in the American College of Surgeons Oncology Group Trial Z0011. *J Clin Oncol*. 2007;25(24):3657-63.
 41. National Comprehensive Cancer Network. NCCN Clinical Practice Guidelines in Oncology (NCCN Guidelines). Breast Cancer. Version 3.2020 - March 6, 2020. Available at: https://www.nccn.org/professionals/physician_gls/pdf/breast.pdf (Accessed on April 29, 2020).
 42. Noguchi M, Noguchi M, Nakano Y, Ohno Y, Kosaka T. Axillary reverse mapping using a fluorescence imaging system in breast cancer. *J Surg Oncol*. 2012;105(3):229-34.
 43. Beek MA, Gobardhan PD, Klompenhouwer EG, Rutten HJT, Voogd AC, Eijt Luiten. Axillary reverse mapping (ARM) in clinically node positive breast cancer patients. *EJSO* 2015; 41:59e63.