

## Mechanical Ventilation Associated Pneumomediastinum – A Rising Incidence of Cases in an Emergency Hospital During the COVID-19 Pandemics

Roxana Crăciun<sup>1</sup>, Cristiana Bogaciu<sup>1</sup>, Vladimir Ciobotaru<sup>1,2</sup>, Anca Nica<sup>1,2</sup>, Alexandru Smaranda<sup>1</sup>, Vlad Constantin<sup>1,2</sup>, Bogdan Socea<sup>1,2</sup>, Alexandru Carâp<sup>1,2</sup>

<sup>1</sup>Department of Surgery, "St. Pantelimon" Emergency Clinical Hospital, Bucharest, Romania

<sup>2</sup>Department of Surgery, "Carol Davila" University of Medicine and Pharmacy, Bucharest, Romania

\*Corresponding author:  
Alexandru Carâp, MD  
Department of Surgery  
"St. Pantelimon" Emergency Clinical  
Hospital, Bucharest, Romania  
E-mail: alexandru\_carap@hotmail.com

### Rezumat

#### *Pneumomediastinul asociat ventilației mecanice – creșterea incidenței cazurilor într-un spital de urgență în timpul pandemiei COVID 19*

*Introducere:* Ventilația mecanică este o ultimă soluție terapeutică în cazul pacienților cu sindrom de detresă respiratorie acută indus de infecția cu virusul SARS-CoV-2. Pneumomediastinul spontan este o patologie rară care se asociază cu ventilația mecanică invazivă. Obiectivul acestui studiu este de a scoate în evidență creșterea incidenței acestei patologii în spitalul nostru pe parcursul celui de-al patrulea val al pandemiei de COVID-19.

*Materiale și metodă:* O evaluare retrospectivă a cazurilor din spital care au necesitat un consult chirurgical a fost realizată prin căutarea în baza de date electronică a instituției după diagnosticul de pneumomediastin în perioada octombrie-noiembrie 2021. Toți pacienții care au avut unul dintre diagnostice de pneumomediastin, au fost incluși în acest studiu.

*Rezultate:* Am indentificat 12 pacienți cu necesar de ventilație mecanică invazivă, care aveau semne de aer liber la nivelul mediastinului pe o tomografie computerizată a toracelui, spitalizați în această perioadă. Toți cei 12 pacienți aveau un tablou clinicoparaclinic de bronhopneumonie SARS-CoV-2, cu leziuni pulmonare extinse. Mortalitatea în rândul acestor pacienți a fost de 58,33% (7 din 12 pacienți).

*Concluzie:* Principalul mesaj al acestui studiu este că incidența pneumomediastinului asociat ventilației mecanice invazive a avut o creștere exponențială pe parcursul valului patru al pandemiei

Received: 17.02.2022

Accepted: 23.05.2022

COVID-19. Considerăm că este necesar un studiu multicentric al acestei patologii pentru o evaluare mai corectă a pacienților și a opțiunilor chirurgicale în cazul acestora.

**Cuvinte cheie:** pneumomediastin, COVID-19, ventilație mecanică

## Abstract

*Introduction:* Mechanical ventilation is a last resort solution for patients presenting with acute respiratory distress syndrome produced by SARS-CoV-2. Spontaneous pneumomediastinum is a rare pathology associated with invasive mechanical ventilation. The objective of our research was to highlight the increased incidence of spontaneous pneumomediastinum during the COVID-19 pandemics in our hospital.

*Material and method:* A retrospective review of the cases in our hospital requiring surgical evaluation was performed. Electronic health records from our institution were searched for nontraumatic pneumomediastinum from October to November 2021. All patients that were identified with pneumomediastinum were included in the review.

*Results:* We identified 12 mechanical ventilated patients that presented with free air in the mediastinum on a computed tomography during the study period. All of the patients had SARS-CoV-2 bronchopneumonia with extensive pulmonary involvement. The mortality rate among these patients was 58.33%.

*Conclusions:* The main take-home message of our study is that the incidence of mechanically ventilation-associated pneumomediastinum was exponentially higher during the fourth wave of COVID-19. There is a need for multicenter data in this pathology for a better approach and to define surgical management options for these patients.

**Key words:** pneumomediastinum, COVID-19, mechanical ventilation

## Introduction

Mechanical ventilation is a last resort solution for patients presenting respiratory failure. During the pandemic of severe acute respiratory syndrome coronavirus 2 (SARS-CoV-2), approximately 2 percent of the patients diagnosed with this infection were admitted to the Intensive Care Unit (ICU) for an acute respiratory distress syndrome (ARDS), with a large proportion of them being intubated and mechanically ventilated, according to the United States Center for Disease Control and Prevention (CDC) (1-4).

Pneumomediastinum is defined by the presence of air in the mediastinum and could be caused by a macroscopic lesion of the upper respiratory tract, but it can also be spontaneous without any obvious factors. Spontaneous

pneumomediastinum (SPM) was first described in 1939 in a postpartum patient (5), but it was not very well understood until 1944 when Macklin et al came up with an answer: the increased alveolar pressure caused alveoli to rupture and release air dissecting the tissues around bronchi and vessels up to the mediastinum (6).

The incidence of SPM is 1/25000 in ages between 5-34 years (7), being more frequent in the young male population, around three-quarters of the patients. Another risk factor for pneumomediastinum is pre-existing respiratory diseases, like asthma, COPD, etc (8).

An observational study by Belletti et al on critically ill, invasively ventilated patients with COVID-19 ARDS showed that pneumomediastinum occurred in 11.2% of patients without any lesions to the upper airways (9).

The objective of our research is to highlight the increasing incidence of pneumomediastinum in ARDS patients induced by SARS-CoV-2 infectious in our hospital, an emergency surgical hospital with no infectious disease ward.

## Materials and Method

A retrospective review of COVID-19 cases included all patients that required a hospital stay, receiving thoracic CT scans, at the height of the fourth wave of the COVID-19 pandemic in Romania (01.10.2021-10.11.2021). Electronic health records and imaging databases from our institution were searched for injuries caused by mechanical ventilation. For all the patients identified, we inventoried demographic data, timing, and type of thoracic injuries, clinical outcome, days to discharge or death, and the need for surgical intervention.

## Results

We identified a total of 12 cases of nontraumatic pneumomediastinum out of 314 COVID-19 patients that required a hospital stay and received CT scans at our institution (3.82%). All patients received mechanical ventilation. There were no cases identified in mechanically ventilated patients with a negative RT-PCR test for SARS-CoV-2.

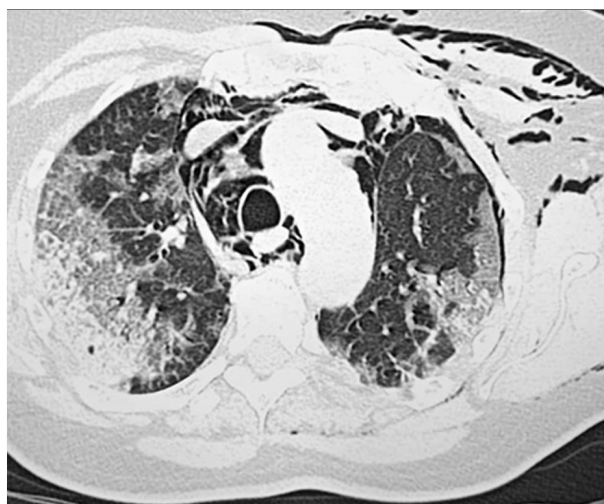
The mean patient age was 67.41 years (range 47-76). Out of these 58.33% were male patients and 41.67% were female. 8 patients showed a lung involvement of at least 50-75% at the initial CT scan, 3 patients had over 75% lung involvement, and 1 had 25-50% involvement.

All of the patients identified had several comorbidities, 91.66% had cardiovascular disease including hypertension, post-acute myocardial infarction fibrosis, atrial fibrillation, heart failure and extensive atherosclerosis, 45.45% had previous pulmonary pathologies like asthma, chronic obstructive pulmonary disease or pulmonary hypertension associated with heart failure. Three of the 12 patients were admitted into our hospital for a diagnosis of acute abdomen requiring emergency surgery:

two of them had presented with intestinal occlusion. The post-operative diagnoses were small intestine volvulus on an adhesive disease for the first patient, a 58-year-old male, and obstructive left colon tumor for the second one, an 87-year-old female. The third patient requiring surgery on admission was a 50-year-old female, with obesity that presented with perforated sigmoidal diverticulitis.

Obesity was another risk factor presenting in 7 out of the 12 patients and one of them was known with metastatic rectal cancer, in palliative care. None of the patients had a complete vaccinal schema.

The most common clinical sign identified was subcutaneous emphysema (75% of patients) as seen in *Fig. 1*. Two of the cases required surgical intervention (for drainage of associated pneumothorax). Other patients requiring surgical interventions after mechanical ventilation were two patients with pneumoperitoneum that received exploratory laparotomies, with no intra-abdominal lesions that could explain the pneumoperitoneum. There was a third case of pneumoperitoneum in a 66-year-old male, where a watch-and-wait protocol was implemented due to the lack of signs of an acute abdomen, even after the decubitalization for diagnostic purposes.



**Figure 1.** Subcutaneous emphysema associated with pneumomediastinum

The mortality rate among these patients was 58.33% (7 out of 12 patients), higher than in other similar studies (10). One out of the 2 patients requiring diagnostic laparoscopy died after 3 days after pulmonary complications.

The mean length of stay for these patients in the ICU was 10.75 days (range 2-24 days) before their transfer to another unit or death. For the 5 patients that survived, there were required between 10 and 23 days before discharge from our unit to recovery units or home.

## Discussions

The COVID-19 pandemic has greatly increased the number of nontraumatic pneumomediastinum cases at our institution, with 12 cases at the peak of the last wave of the pandemic (in 41 days) versus 2 cases between 01.01.2018-01.01.2019 with mortality over 50%.

Considering that all these cases received a surgical consult it is important to understand the difference between the malignant and benign forms. Nontraumatic pneumomediastinum is a rare condition. It has a higher incidence among patients with acute respiratory distress that require invasive ventilation (11-14). The increased alveolar pressure causes alveoli to rupture and release air dissecting the tissues around bronchi and vessels up to the mediastinum (6). Surgical decompression is only required if cardiac tamponade or airway compression occurs (15-17). None of the patients required surgical intervention for pneumomediastinum.

In extremely rare cases pneumomediastinum can cause pneumorrhachis (18) and pneumoperitoneum (19). The need for surgical intervention in those cases associating pneumoperitoneum should be carefully evaluated and postpone the intervention in the absence of acute abdomen signs or other symptoms raising the suspicion of a cavitory viscus lesion.

All the patients we identified in our evaluation of the electronic database had several comorbidities: cardiovascular, pulmonary,

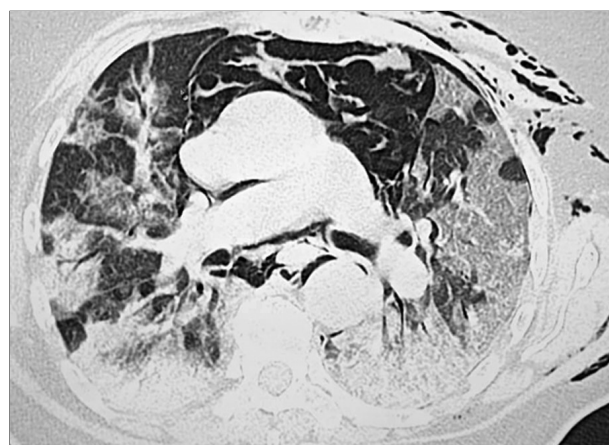
neoplasia or obesity and had no complete vaccinal schema against SARS-CoV-2, which sustains the results of McGuinness et al, in their 2020 study (20).

The study has multiple limitations including that it is a retrospective study therefore no causal inferences could be made. The small number of analyzed cases is another, explained by the fact it was a single-center study, in an emergency surgical hospital and not an infectious disease institution. Also, a lack of case identification in our electronic health records due to the search engine could be another limitation.

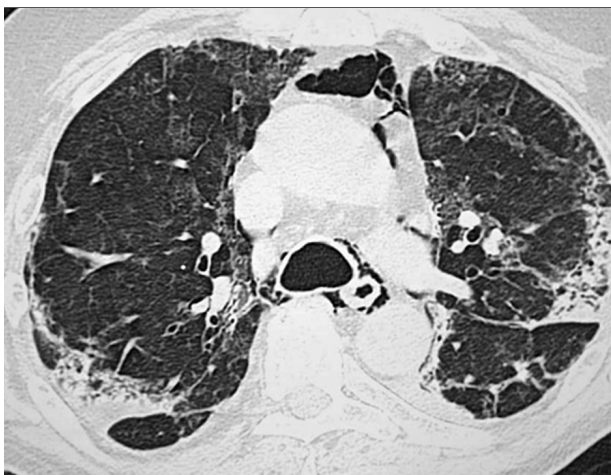
## Conclusions

There is an increased incidence of barotrauma in COVID-19 patients that require mechanical ventilation (14) leading to mediastinal, pleural, and other virtual spaces injuries. COVID-19 patients developing pneumomediastinum have a high degree of pulmonary involvement, most patients showed a lung involvement of at least 50% at the initial CT scan (*Figs. 2, 3*).

Nontraumatic pneumomediastinum is a rare condition that has a greater incidence in COVID-19 infection patients that require mechanical ventilation compared with the general population. None of the patients identified required surgical treatment for tension pneumomediastinum, but two required surgical drainage of associated tension



**Figure 2.** Large pneumomediastinum in a 73 years old male



**Figure 3.** Pneumomediastinum associated with extensive pulmonary involvement in a 65 years old woman

pneumothorax and two required diagnostic laparoscopies for associated pneumoperitoneum.

There is a need for multicenter data in this pathology for a better approach and to define surgical management options for these patients.

### *Conflicts of Interests*

The authors declare no conflicts of interests.

### *Ethics Approval*

All procedures performed were in accordance with the ethical standards of the 1964 Helsinki Declaration and its later amendments.

### **References**

1. Stokes EK, Zambrano LD, Anderson KN, Marder EP, Raz KM, El Burai Felix S, et al. Coronavirus Disease 2019 Case Surveillance - United States, January 22-May 30, 2020. *MMWR Morb Mortal Wkly Rep.* 2020;69(24):759-765.
2. CDC COVID-19 Response Team. Severe Outcomes Among Patients with Coronavirus Disease 2019 (COVID-19) - United States, February 12-March 16, 2020. *MMWR Morb Mortal Wkly Rep.* 2020;69(12):343-346.
3. Garg S, Kim L, Whitaker M, O'Halloran A, Cummings C, Holstein R, et al. Hospitalization Rates and Characteristics of Patients Hospitalized with Laboratory-Confirmed Coronavirus Disease 2019 - COVID-NET, 14 States, March 1-30, 2020. *MMWR Morb Mortal Wkly Rep.* 2020;69(15):458-464.
4. Zangrillo A, Beretta L, Scandroglio AM, Monti G, Fominskiy E, Colombo S, et al. Characteristics, treatment, outcomes and cause of death of invasively ventilated patients with COVID-19 ARDS in Milan, Italy. *Crit Care Resusc.* 2020;22(3):200-211.
5. Hamman L. Spontaneous mediastinal emphysema. *Bull Johns Hopkins Hosp* 1939;64:1-21.
6. Macklin MT, Macklin CC. Malignant interstitial emphysema of the lungs and mediastinum as an important occult complication in many respiratory diseases and other conditions: an interpretation of the clinical literature in the light of laboratory experiment. *Medicine* 1944; 23:281-358
7. Macia I, Moya J, Ramos R, Morera R, Escobar I, Saumench J, et al. Spontaneous pneumomediastinum: 41 cases. *Eur J Cardiothorac Surg.* 2007;31(6):1110-4.
8. Kobashi Y, Okimoto N, Matsushima T, Soejima R. Comparative study of mediastinal emphysema as determined by etiology. *Intern Med.* 2002; 41(4):277-82.
9. Belletti A, Palumbo D, Zangrillo A, Fominskiy EV, Franchini S, Dell'Acqua A, et al. Predictors of Pneumothorax/ Pneumomediastinum in Mechanically Ventilated COVID-19 Patients. *J Cardiothorac Vasc Anesth.* 2021;35(12):3642-3651.
10. Brito J, Gregorio P, Mariani A, D'ambrosio P, Filho M, Ferreira L, et al. Pneumomediastinum in COVID-19 disease: Outcome and relation to the Macklin effect. *Asian Cardiovascular Thorac Ann* 2021;29(6): 541-548.
11. Chu CM, Leung YY, Hui JY, Hung IF, Chan VL, Leung WS, et al. Spontaneous pneumomediastinum in patients with severe acute respiratory syndrome. *Eur Respir J.* 2004;23(6):802-4.
12. Wintermark, M, Schnyder, P. The Macklin effect. *Chest.* 2001;120:543-547
13. Sakai M, Murayama S, Gibo M, Akamine T, Nagata O. Frequent cause of the Macklin effect in spontaneous pneumomediastinum: demonstration by multidetector-row computed tomography. *J Comput Assist Tomogr.* 2006; 30(1):92-4.
14. Simpson S, Kay FU, Abbara S, Bhalla S, Chung JH, Chung M, et al. Radiological Society of North America Expert Consensus Document on Reporting Chest CT Findings Related to COVID-19: Endorsed by the Society of Thoracic Radiology, the American College of Radiology, and RSNA. *Radiol Cardiothorac Imaging.* 2020;2(2):e200152.
15. Kouritas VK, Papagiannopoulos K, Lazaridis G, Baka S, Mpoukovinas I, Karavasilis V, et al. Pneumomediastinum. *J Thorac Dis.* 2015;7(Suppl 1): S44-9.
16. Shennib H, Barkun A, Matouk E, Blundell PE. Surgical decompression of a tension pneumomediastinum. *Chest.* 1988;93(6):1301-2.
17. Dondeliner RF, Coulon M, Kurdziel JC, Hemmer M. Tension mediastinal emphysema: emergency percutaneous drainage with CT guidance. *Eur J Radiol.* 1992;15(1):7-10.
18. Al-Mufarrej F, Gharagozloo F, Tempesta B, Margolis M. Spontaneous cervicothoracolumbar pneumorrhachis, pneumomediastinum and pneumoperitoneum. *Clin Respir J.* 2009;3(4):239-43.
19. Lantsberg L, Rosenzweig V. Pneumomediastinum causing pneumoperitoneum. *Chest.* 1992;101(4):1176.
20. McGuinness G, Zhan C, Rosenberg N, Azour L, Wickstrom M, Mason DM, et al. Increased incidence of barotrauma in patients with COVID-19 on Invasive Mechanical Ventilation. *Radiology.* 2020;297(2): E252-E262.