

## Laparoscopic Restorative Proctocolectomy for Ulcerative Colitis - How I Do It?

Oana Stanciulea<sup>1</sup>, Mihai Adrian Eftimie<sup>1,2\*</sup>, Iulian Mosteanu<sup>1</sup>, Robert Ciortan<sup>1</sup>, Irinel Popescu<sup>1</sup>

<sup>1</sup>Department of General Surgery, Fundeni Clinical Institute, Bucharest, Romania

<sup>2</sup>"Carol Davila" University of Medicine and Pharmacy, Bucharest, Romania

\*Corresponding author:  
Mihai Adrian Eftimie, MD  
Department of General Surgery  
Fundeni Clinical Institute  
Bucharest Romania  
E-mail: [mihai.eftimie84@gmail.com](mailto:mihai.eftimie84@gmail.com)

### Rezumat

#### *Proctocolectomia totală restaurativă prin abord laparoscopic – tehnică chirurgicală*

Proctocolectomia totală restaurativă cu rezervor ileal și anastomoză ileoanală este în zilele noastre tratamentul "gold standard" la pacienții cu colită ulcerativă care au indicație de tratament chirurgical. Intervenția este tehnic dificilă și este asociată cu o rată semnificativă de morbiditate și mortalitate. Pentru a obține rezultate bune, momentul în care se efectuează intervenția chirurgicală este extrem de important. În ultimele decenii, odată cu răspândirea tehnicilor de chirurgie minimal invazivă, această procedură se poate efectua prin abord laparoscopic, fiind asociată cu toate avantajele pe termen scurt pe care le aduce această cale de abord. Laparoscopia aduce și avantaje pe termen lung - prezervă într-o proporție mai mare de cazuri funcția fertilă și conduce la formarea a mai puține aderențe postoperatorii - de aceea este recomandată în prezent și de ghidurile Asociației Europene de Crohn și Colită, în centre unde există experiență.

Cuvinte cheie: laparoscopie, proctocolectomie restaurativă, colită ulcerativă, rezervor ileal, chirurgie colo-rectală

### Abstract

Total proctocolectomy with ileal pouch anal anastomosis (IPAA) is nowadays the gold standard in patients with ulcerative colitis requiring surgery. It is a complex procedure, being associated with a significant rate of morbidity and mortality. In order to obtain

Received: 26.04.2022  
Accepted: 15.06.2022

better results, the timing of surgery is essential. In the last decades, with the expansion of the minimally invasive techniques, the procedure can be performed feasible and safe by laparoscopy, bringing all the short term advantages associated with this approach. Due to the long term advantages regarding improved female fecundity function and fewer adhesions the laparoscopic approach is now recommended by the European Crohn's and Colitis Organization in centers with appropriate expertise.

**Key words:** laparoscopy, restorative proctocolectomy, ulcerative colitis, ileal pouch, colorectal surgery

## Introduction

Ulcerative colitis is a chronic disease characterized by inflammation of the colorectal mucosa. The incidence and prevalence over the past years in Romania has been on the rise, ulcerative colitis being more frequent than Crohn's disease (1).

Most cases can be successfully treated medically, but still up to 30% of cases will require surgical intervention (2). Due to significant improvement in medical therapy (adoption of biologics) some authors have reported a reduced risk of surgery (3).

The most important question to be raised is "biologics really decrease the need for surgery or only delay the necessity of surgery, potentially at the cost of increasingly severe malnourishment and chronic illness at the subsequent time of operation?"(3)

The timing of surgery it is of the utmost importance, delay in surgery timing being associated with a deterioration of the patient's condition and subsequently with increased postoperative morbidity.

### *Short History of the Procedure*

The first total restorative proctocolectomy with a ileal pouch anal anastomosis IPAA was reported by Parks et al (4) in 1978 representing an important milestone for the surgical treatment of ulcerative colitis. Up to that point all the procedures were performed with an ileo-anal anastomosis, being associated with poor functional outcome. At that time the

minimally invasive techniques emerged and they were gaining acceptance in different pathologies, leading to the performance of the first laparoscopic proctocolectomy with ileal pouch anal anastomosis in 1992 (5).

Due to the technical difficulty of the procedure it was necessary to accumulate surgical experience and with the development of laparoscopic equipment the procedure is gaining acceptance, being widely, nowadays, performed in high volume centers.

In our country the first open restorative proctocolectomy for ulcerative colitis was performed in 1991 by Mihnea Ionescu (6-8).

In 2019 the same authors published the results of the most extensive series of Romanian patients with open restorative proctocolectomy. (Technical Issues and Early Outcomes of Restorative Proctocolectomy for Familial Adenomatous Polyposis and Ulcerative Colitis: The Largest Romanian Single-Team Experience.

Our first successful laparoscopic total proctocolectomy with IPAA was performed in 2014 for familial adenomatous polyposis and in 2016 for ulcerative colitis.

## Materials and Methods

### *Indications for Surgery*

The main indications for surgery in ulcerative colitis are: disease that is refractory to medical treatment and acute severe ulcerative colitis (2). In clinical practice we noticed in the last years an increase in the number of acute

severe colitis requiring surgery. The absolute indications for surgery are: toxic megacolon, uncontrolled bleeding, perforation and dysplasia / malignancies. Other, less frequent indications include: extraintestinal manifestations, side effects of the medication, poor drug compliance.

### *Surgery for the treatment of UC - Choice of the procedure. Indications and contraindications for the laparoscopic approach*

Laparoscopic restorative proctocolectomy (LRP) is the procedure of choice for patients with ulcerative colitis requiring surgery. In selected cases, total proctocolectomy with end-ileostomy (TPEI) may be offered to patients (2) with contraindications of ileal pouch anal anastomosis (carcinoma of the low rectum that require abdomino-perineal resections, anal sphincter incompetence) (8). The surgical team must also take into account the patients preference - usually, LRC requires 2 or 3 steps and it is associated with a significant number of complications (incontinence, leaks, pouchitis, pouch failure). TPEI can also be performed by laparoscopic approach, being associated with parastomal hernias, ileostomy prolapse and perineal wound healing problems (9).

Technically, LRP may be performed in one, two or three stages.

A one-stage operation involves a total proctocolectomy with an IPAA reconstruction in the same procedure without a loop ileostomy; its use in clinical practice is limited due to the patient's condition at the time of surgery and treatment (corticosteroids, biologics).

A two-stage procedure consists of a total proctocolectomy and IPAA with a diverting loop ileostomy. This loop ileostomy is reversed in the second part of the two-stage procedure at a later date, usually at 2-3 months (if the first stage is uneventful). The two steps procedure is the standard of care in elective settings, as long as the patient has no malnutrition, significant anaemia or recent

high dose steroid exposure (3).

A three-stage procedure consists of a total colectomy, which is followed in the second stage of the procedure by a completion proctectomy with IPAA and diverting loop ileostomy. The diverting loop ileostomy is reversed in a third surgery. Usually the three-stage procedure is performed in emergency settings, for patients with poor biological status, patients who have received high doses of steroids or immunosuppressive agents (2,3,10).

The modified two-stage IPAA is an alternative to one-stage, two-stage, and three-stage ileal pouch anal anastomosis, being currently recommended by the ECCO guidelines (2).

There is a trend showing that this surgical approach it is associated with improved results in terms of anastomotic leak rates, postoperative septic complications and small-bowel obstruction rates, when compared with two-stage and three-stage IPAA (11,12).

Laparoscopy is associated with short term benefits: lower postoperative morbidity, faster recovery, reduction in postoperative pain and analgesia consumption, shorter hospitalization and better cosmetic appearance. Due to the long term advantages regarding improved female fecundity function and fewer adhesions, the laparoscopic approach is now recommended by the European Crohn's and Colitis Organization in centers with appropriate expertise.

The main contraindication for a laparoscopic approach is the presence of toxic megacolon or perforation with secondary peritonitis. Fortunately, these circumstances are less common in clinical practice. Previous abdominal surgeries performed by open and minimally invasive approach are not a contraindication for the use of laparoscopy.

Selection of the procedure depends on the experience of the team, stage of the disease, current cardiovascular and septic status of the patient (3). Delayed surgical approach can be associated with increased cost costs due to higher morbidity and longer hospitalization.

## Preoperative Preparation - Optimization of the Patient Status

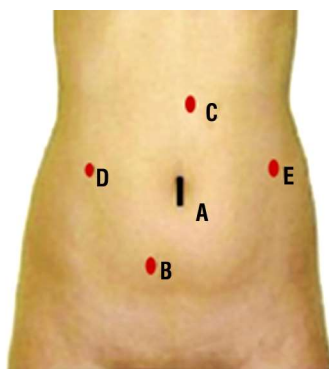
Whenever possible, especially in elective settings it is important to identify and correct the factors associated with increased post-operative morbidity and mortality: impaired nutritional status, anemia, low albumin levels, steroids should be weaned before surgery. Prophylactic anticoagulation therapy is recommended in hospitalized patients with UC due to a higher risk of thromboembolic events (2).

## Surgical Technique for Laparoscopic Two Stage Procedure

### Patient position and port placements (Fig. 1)

The patient is placed in Trendelenburg position with low lithotomy, legs apart and placed on mounts at the level of the operating table in order to facilitate access of the operating surgeon. Both arms are tucked in on the side of the patient. Correct positioning and anchorage of the patient must be performed because various positions and inclinations of the table are used during the procedure in order to obtain adequate exposure. Padded supports are applied to the shoulders.

We usually use two monitors on both sides of the patient. IV lines have extensions. The



**Figure 1.** Trocar placement  
Trocar A – Optical port – 10 mm;  
Trocar B – working port – 10-12 mm;  
Trocar C – assistant port – 5 mm;  
Trocar D – working port – 10-12 mm;  
Trocar E – working port – 10 -12 mm.

urinary bladder is catheterized. Access on both sides of the patient and between the legs must be easy in order to allow changes in positions for the team members.

A three surgeon team is usually enough for this type of procedure: main surgeon, camera surgeon and assistant surgeon.

In order to obtain pneumoperitoneum, a Veress needle is inserted in the abdominal cavity at the place of Trocar A, that will become the optical trocar. A 30-degree angle telescope is used along with 5 mm operating instruments.

Trocar B and D are usually the operating trocars and can have 10-12 mm in diameter. Depending on the segment of colon or rectum that needs to be operated, trocars C and E can also become operating trocars. They are usually used by the assistant surgeon for traction or suction.

At the place of trocar D, the ileostomy (terminal or protective) is usually extracted.

### Operative steps

The surgical procedure is divided in three major steps:

1. Laparoscopic mobilization and resection of the colon, terminal ileon and rectum. The resection part is performed in a counter clockwise approach, beginning with the mobilization and resection of the left colon and rectum;
2. Specimen extraction and creation of the pouch – hand - sewn or using linear staplers;
3. Mechanical anastomosis between the pouch and the rectum and ileostomy formation.

### Total Colectomy and Rectal Resection

The rectum, the whole colon and the terminal part of the ileum need to be completely mobilized in order to facilitate vascular control, extraction and reconstruction using a pouch.

The first step of the resection part is represented by the left colectomy. Both

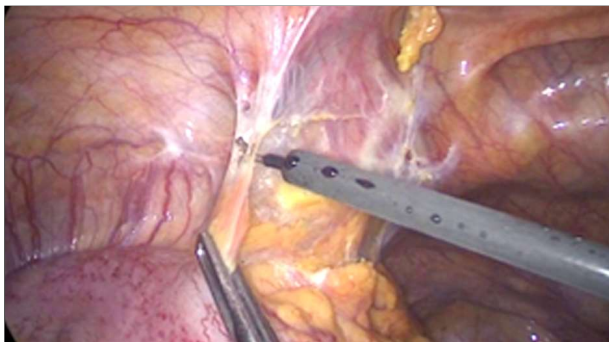
operating surgeon and camera surgeon are placed on the right side of the patient. Trocar A is for the camera and trocars B and D are used as operating trocars. The assistant surgeon is placed on the left side of the patient. The patient is placed in a Trendelenburg position and the table is inclined to the right side of the patient.

Dissection is performed using the monopolar hook, ultrascision device or with a 5 or 10 mm Liga-Sure™.

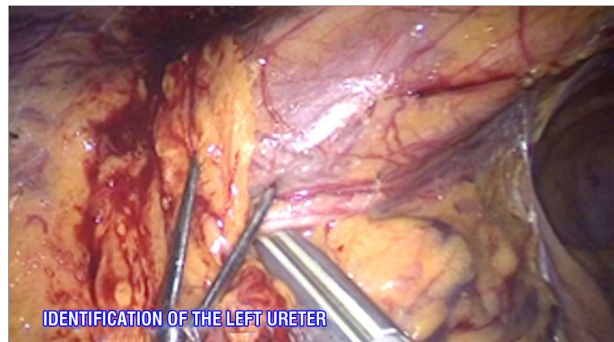
We start with the dissection of the lateral attachments of the sigmoid and descending

colon (*Fig. 2*) At this step of the procedure, the left ureter is identified and preserved (*Fig. 3*). The left aspect of the colon is pulled medially by the operating surgeon and the peritoneal adhesences are dissected using the monopolar hook until splenic flexure is partially mobilized from the inferior (*Fig. 4*). Care must be taken to preserve the genital vessels.

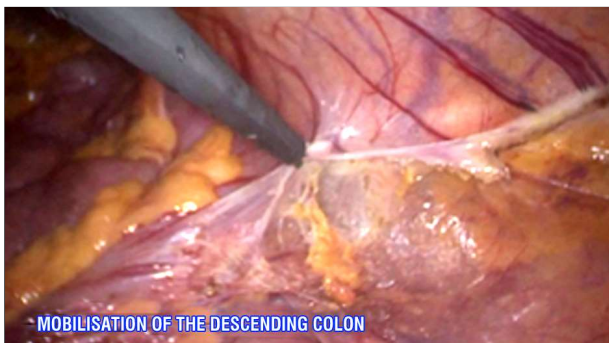
After finishing the lateral mobilisation of the descending and sigmoid colon, the procedure continues with medial control of the sigmoid and left colic vessels. The sigmoid vessels are identified, clipped using medium



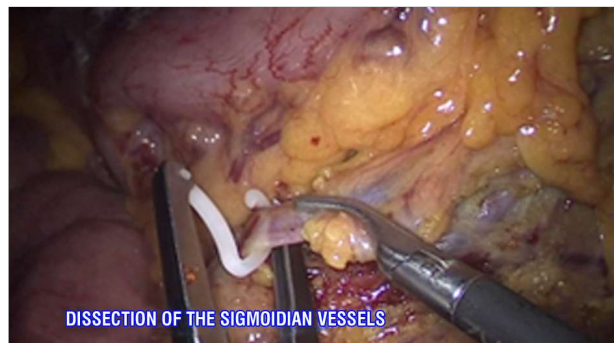
**Figure 2.** Sigmoid colon mobilization lateral to medial



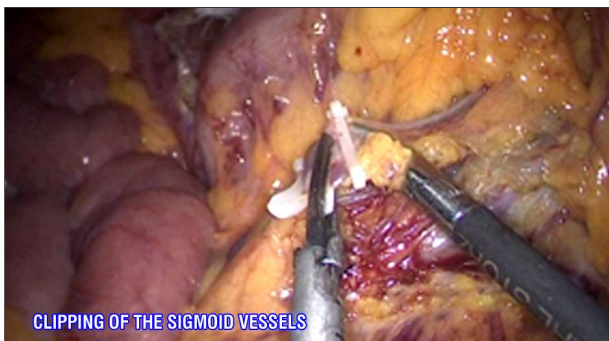**Figure 3.** Identification of the left ureter



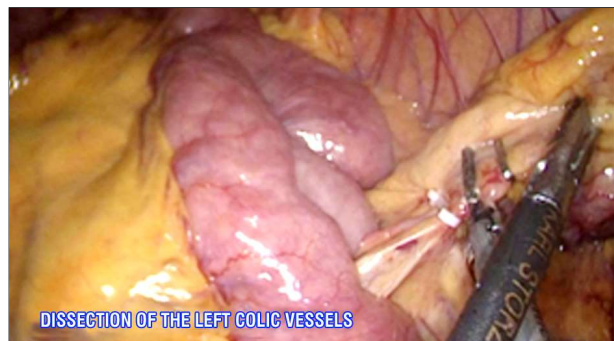
**Figure 4.** The descending colon is mobilized using monopolar hook



**Figure 5.** Dissection of the sigmoidian vessels



**Figure 6.** Clipping and sectioning of the sigmoid vessels



**Figure 7.** The left colic vessels are clipped and sectioned

size Hemo-Locks™ and sectioned (Figs. 5,6) Vascular control is continued with the left colic vessels. The same control technique is used upon them as well (Fig. 7). If there are no signs of dysplasia or malignancy, there is no need for a radical interception of the inferior mesenteric vessels. The mesocolon is controlled using the Liga-Sure™ or clips.

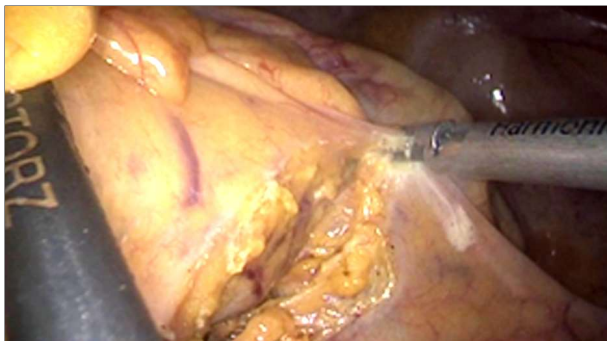If the left colon has any suspicion of malignancy, vascular control must be made at the origin of the inferior mesenteric artery from the aorta using medium or large size Hemo-Locks™ clips. Lymph nodes from the origin of the inferior mesenteric artery need to be sent to pathological examination for correct oncological staging. The inferior mesenteric vein is identified, clipped and sectioned at the inferior border of the pancreas. The left colon needs to be completely mobilized from its adherences with the Gerota fascia.

After freeing up the lateral attachments of the descending and sigmoid colon, we perform a downwards dissection of the recto-sigmoidian junction and of the superior rectum (Fig. 8). At

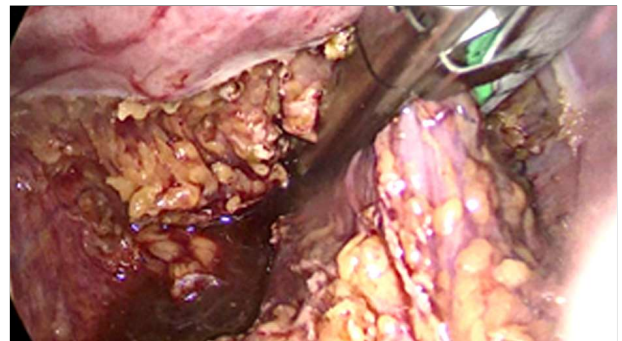
this step of the procedure great care in preserving the hipogastric nerves must be taken, in order to prevent urinary and fertile complications. There is no need for a TME excision for patients with no signs of malignancy of the rectum or recto-sigmoidian junction. Vascular control and dissection is performed in the proximity of the rectum (Close rectal dissection) in order to obtain a nerve sparing procedure with good urinary and sexual results (Fig. 10). Anterior dissection is performed posteriorly from the Denonvillier's fascia in males and between the rectum and the posterior wall of the vagina in females using monopolar cautery.

The rectum is transected using one or two purple Endo-GIA cartridges of 45 or 60 mm, at the level of the pelvic floor, if a reconstructive phase is taken into account in the same procedure (Fig. 9, 11, 12). Transection of the rectum can be postponed and performed at the time of specimen removal through the Pfannensteil incision.

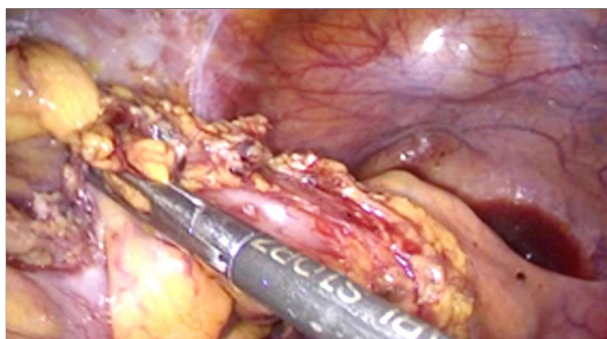
The procedure continues with the reposit-



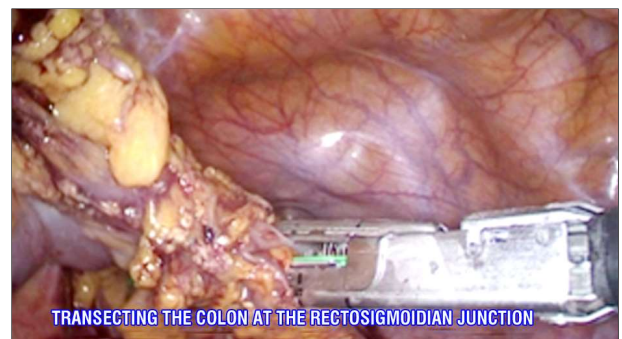**Figure 8.** Dissection of the recto-sigmoidian junction



**Figure 9.** The rectal stump is stapled at the level of the anal canal



**Figure 10.** The recto-sigmoidian junction is cleared and prepared to be stapled



**Figure 11.** The rectosigmoid junction is transected with Endo-Gia stapler

tioning of the operative team and of the patient. The main surgeon is located between the patient's legs using trocars E and D as operative trocars. Camera surgeon is placed on the right side of the patient. The assistant uses trocar C for traction of the great omentum and stomach. The patient is brought up in a Reverse-Trendelenburg position, maintaining the right side inclination of the operative table.

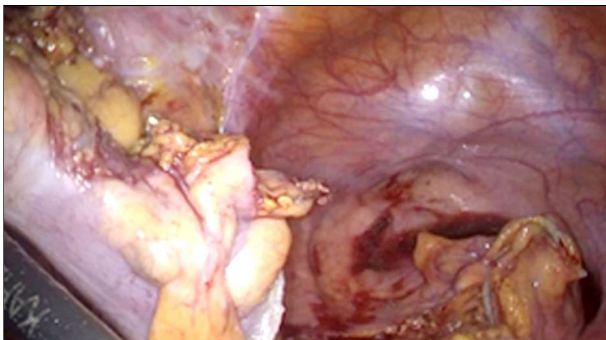
Entrance into the omental bursa is obtained by division of the gastro-colic ligament at the level of the distal one third of the transverse colon. Dissection is done using the ultrasonic device or the Liga-Sure™ (Fig. 13). The splenic colonic flexure is completely mobilized from the right side to the left by close dissection and vascular control. A mixt approach of the splenic flexure of the colon from both left and right side can be taken into account if close adherences with the spleen are encountered.

Meticulous dissection must be performed at

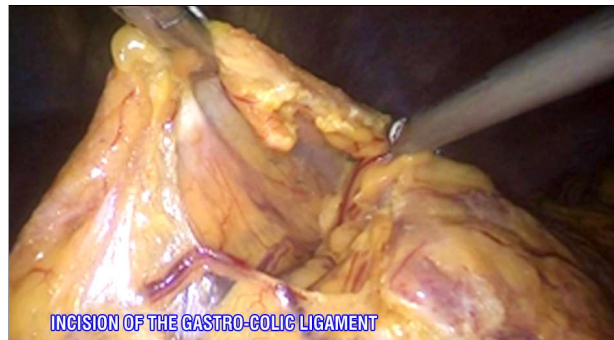
this point of the procedure, in order not to harm the inferior margin of the pancreas or the spleen. Adherences and vascular bridges must be carefully controled using Liga-Sure™ (Fig. 14).

The dissection of the gastro-colic ligament is continued to the right of the transverse colon, after the patient is inclined to the left side. After all of the gastro-colic adherences are freed up, using ultrasonic shears or the Liga-Sure™, the transverse colon is held up by the assistant surgeon in order to evidentiate the mid colonic vessels. Vascular dissection of these is obtained using the monopolar hook. Mid size Hemo-Locks™ clips are used (Figs. 15, 16). The vein and the artery are taken down separately. The Liga-Sure™ is used for transverse meso-colon transection and vascular control. Right and left branches of the mid colonic pedicle, can be managed in a separate manner, if there are no sign of transverse colon malignisation.

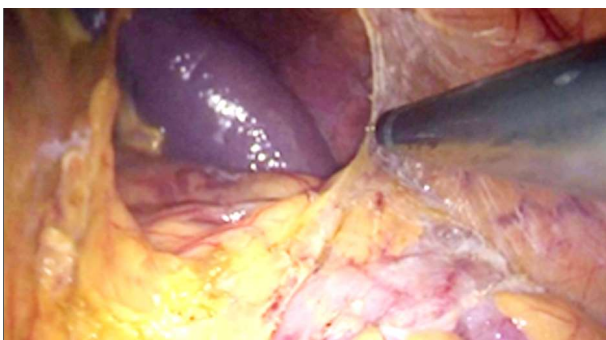
Colonic hepatic flexure mobilization is



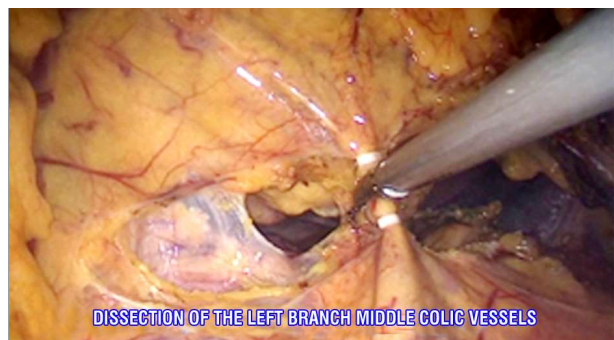**Figure 12.** Proximal and distal stump of rectosigmoid junction



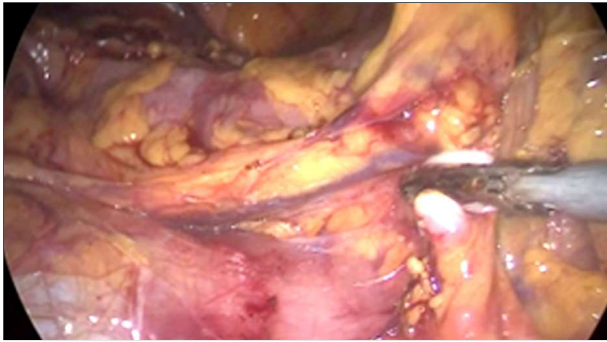
**Figure 13.** Gastro-colic ligament is sectioned and the takedown of the left colic flexure is continued using medial to lateral approach



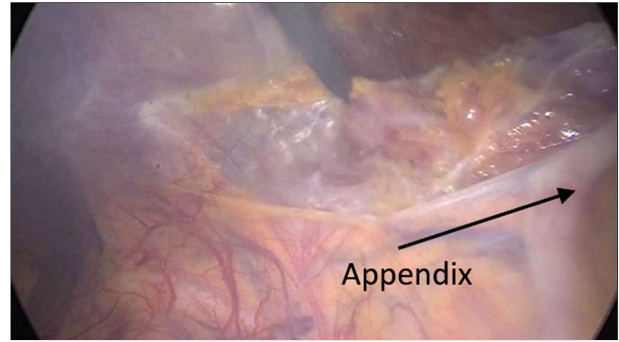
**Figure 14.** Dissection and takedown of the left colic flexure



**Figure 15.** The transvers colon is pulled upwards and the left branch of the middle colic vessel is clipped and sectioned



**Figure 16.** Right branch of middle colic vessels are clipped and sectioned



**Figure 17.** The ascending colon is mobilized from lateral to medial and inferior to superior approach

started at this step, from the left side, and finished after repositioning the operative team and the patient.

For right colon and ileal mobilization, the operative surgeon changes position from between the legs of the patient to the left side. The camera surgeon remains on the left side and the assistant surgeon on the right side of the patient.

The operative table is placed in a Trendelenburg position with a left side inclination. The intestines are placed on the left side of the patient.

The ascending colon, the caecum and the final intestinal loop of the ileon are mobilized by dissection of their parietal and retroperitoneal adherences, in a lateral to medial and inferior to superior approach (*Fig. 17*). Right colic and terminal ileal vessels must be preserved in order to spare as much of the small bowel as possible, thus permitting a

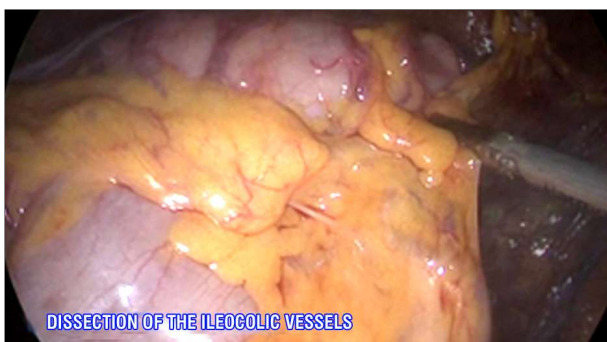good pouch creation. Care must be taken to avoid injury to the duodenum, right gonadal vessels and right ureter.

Vascular control of the right mesocolonic and ileocolic vessels is performed near the the colon using clips and the Liga-Sure™, only if there is no sign of malignancy (*Fig. 18, 19*). Otherwise, vascular control is obtained in an oncological manner, high vascular dissection and total mesocolic resection can be taken into account.

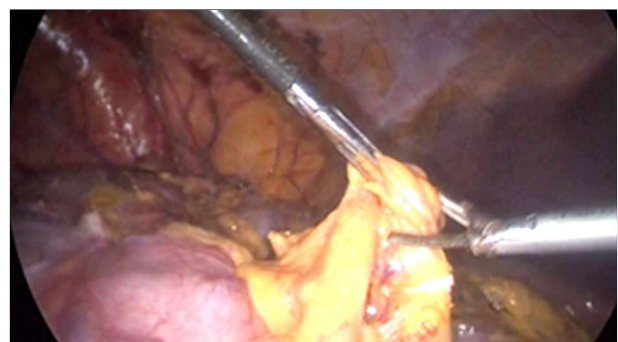
#### *Specimen extraction and creation of the pouch*

After complete mobilisation of the colon and rectum the specimen is extracted through a Pfannensteil incision of 7-8 cm, protected by a mid size Alexis™ wound-protector that is also a good retractor – for a two stage procedure.

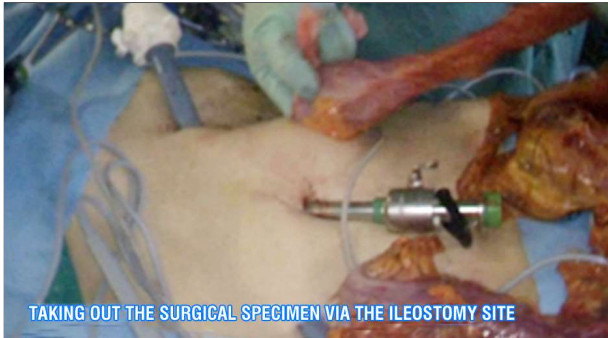In the case of a three-stage procedure the specimen is extracted through a small incision



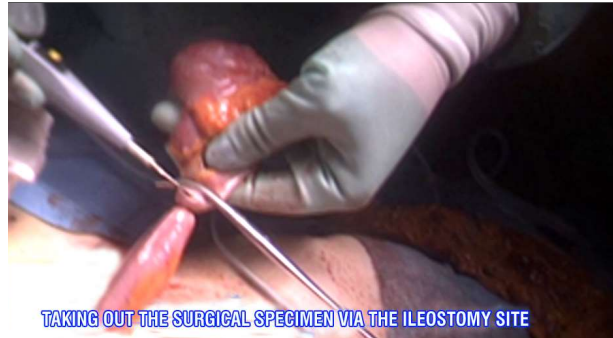**Figure 18.** The ileocolic vessels are identified



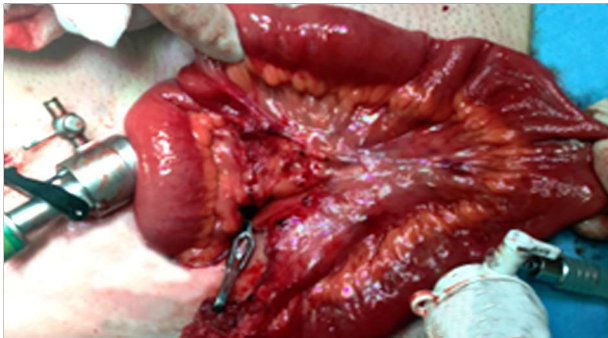**Figure 19.** Ileocolic vessels are clipped and sectioned



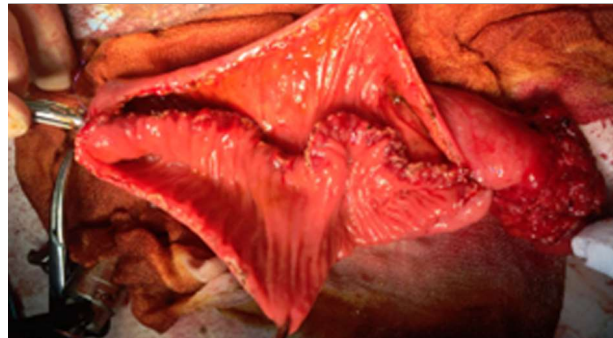
**Figure 20.** An incision in the right quadrant for the future ileostomy is performed and the colon specimen is being pulled through this incision



**Figure 21.** Distal ileum is sectioned



**Figure 22.** The last ileal loop is pulled through a Pfannenstiel incision and the length of the future pouch is checked



**Figure 23.** The posterior layer of the "J" pouch is fashioned and the circular stapler anvil is inserted

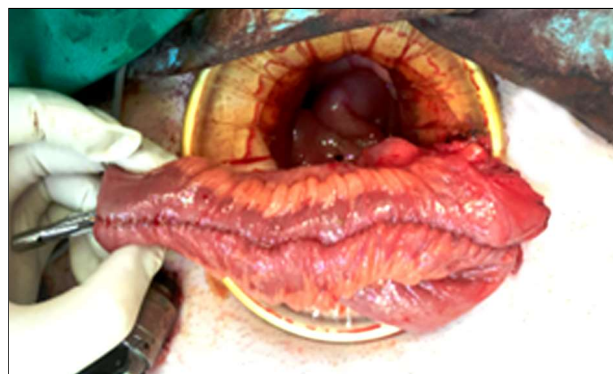made in the right hypochondrium. After minimal calibration of the site using separated wires, this place becomes the end-ileostomy site (Figs. 20, 21)

The site for the ileal transection is chosen in concordance with remaining vascularization of the terminal ileum and caecum. We usually use an Endo-GIA™ blue cartridge stapler of 45 mm.

The small intestine is displayed on the abdomen and the creation of the pouch is started. A hand-sewn "J-Pouch" with a length of 15 to 20 centimetres is performed. The apex of the pouch is chosen, the place where the anvil of the circular stapler is inserted for the ileo-rectal anastomosis (Fig. 22).

The pouch creation and calibration in length is started with the posterior wall in a continuous side-by-side, 2-layer suture using PDS 4-0 (sero-serous and full-thickness) (Fig. 23). The place for the incision on the intestines is chosen at the mid level of the

anti-mesostenic side of the ileum. The anvil of the circular stapler is placed at the distal end of the pouch and secured with a purse-string suture. We normally use a 29 mm circular stapler. After the anvil is safely placed, the anterior wall of the pouch is sutured in a similar manner, using continuous PDS 4-0 sutures (Fig. 24).



**Figure 24.** The "J" pouch is completed and ready for anastomosis

A tension-free pouch-to-rectum anastomosis must be obtained. In order to have this, in some cases, a complete laparoscopic mobilisation of the small intestines from their retroperitoneal adhesences to the third part of the duodenum, near the origin of the superior mesenteric artery must be performed – a Cattell Braasch maneuver. Horizontal incisions of the peritoneum of the mesentery under transillumination, can also provide the length for a tension-free anastomosis. Care must be taken not to injure vascularisation of the pouch (terminal vascularisation of the distal ileum can be intercepted and can lead to necrosis of the pouch). If a tension-free anastomosis is not obtained, ligation of the ileo-colic vessels at the origin from the superior mesenteric artery must be taken into account. One or a combination of these procedures can be performed in the same patient for optimal result using the laparoscopic approach.

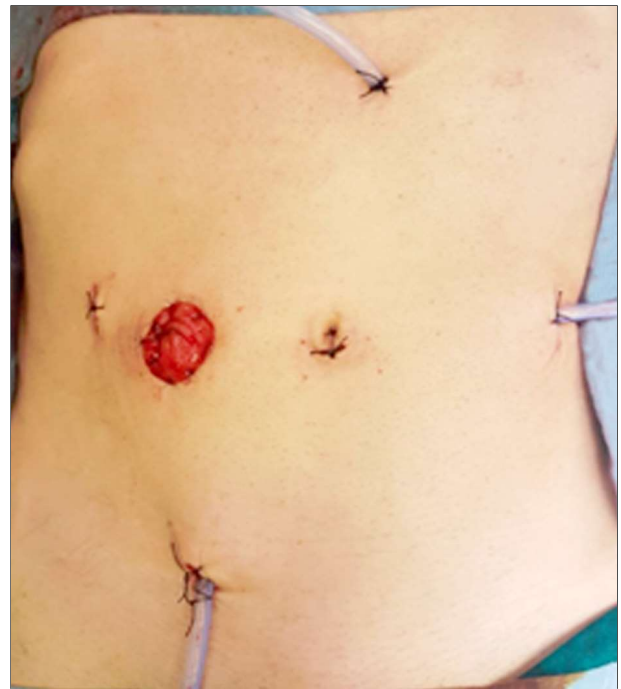The Kirat Manoeuvre (13) – pulling down the apex of the pouch to the rectal stump, where the anastomosis will be – can be useful for evaluating tension in the future anastomotic complex. One can evaluate the length of the pouch by pulling the apex of the stump to the pubic bone. If the apex reaches the pubic bone, or better, is longer, this an indirect sign that the pouch will reach the rectal stump without tension.

### ***Mechanical Anastomosis Between the Pouch and the Rectum and Ileostomy Formation***

After the "J-Pouch" is finished and a tension-free anastomosis is possible, the pouch is inserted in the abdominal cavity.

The ileal pouch-to-rectum anastomosis is then created.

The circular stapler is inserted through the rectal stump and the pin is taken out. The anvil is placed in contact with the pin. The stapler is carefully closed, taking care of surrounding structures not to come between the stapler line and the pouch and mesentery maintaining their orientation, not to get twisted.



**Figure 25.** Postoperative aspect

When the stapler is completely closed the anastomosis is performed. A waiting time of 15 to 30 seconds must be applied before the stapler is opened, for haemostasis. Control of anastomosis and pouch tightness is performed by inserting gas in the rectum, while the pouch and anastomosis are placed under water.

A loop ileostomy is performed. The exteriorisation of the protective ileostomy must be carefully performed in order not to add extra tension on to the pouch-to-rectum anastomosis. The ileostomy is fixed to the abdominal wall by four PDS 4-0 sutures and after closure of the Pfannensteil incision, the ileon is opened and the stoma matured using the same PDS 4-0 separated sutures (*Fig. 25*).

Before closure of the Pfannensteil incision, all of the remaining trocar sites are controlled and closed using a fascia closure device and Vycril-1 sutures. 3 drainage tubes are placed in the peritoneal cavity.

The specimen is sent for pathological examination.

## Discussion / Technical alternatives

### *Alternatives to IPAA*

A total colectomy with ileo-rectal anastomosis can be the solution for younger women who are eager to get pregnant or for patients where the rectum can be spared regarding disease activity. These patients need to have a minimal burden of rectal disease, no signs of dysplasia or cancer, normal sphincter function and a healthy distensible rectum. Pre-operative anorectal manometry needs to be used. Continuous endoscopic surveillance of the remnant rectum needs to be performed.

For young patients is not a definitive procedure, completion proctectomy follows a rectal sparing technique in up to 50 percent of patients (10). Moirera et al (14) found that these patients have few bowel motions than IPAA but have higher rates of urgency and related dietary and work restrictions. It can also be a solution for metastatic malignant disease.

### *Management of the Rectal Stump*

Management of the rectal stump can be difficult. For the majority of modified 2-step or 3-step procedures, the rectum is transected at the level of the sacral promontory and freed up (stapled or sutured) in the abdominal cavity – this is the preferred method of the author.

The creation of a mucous fistula in the left flank reduces the risk for pelvic sepsis (stump blow-out) and thus reduces post-operative morbidity. A long recto-sigmoidian stump exteriorized through the same incision as the terminal ileostomy can be a solution for reduce stump-related morbidity. Another solution for a long rectal stump is to be left closed and put subcutaneously at the inferior margin of the incision site or at the level of the Pfannensteil incision. This setting reduces pelvic sepsis and can lead to a minimal wound infection (2).

A short intra-pelvic rectal stump adds to the complexity of the subsequent proctectomy with or without IPAA.

### *Close Rectal Dissection*

TME is the standard of care for malignant rectal disease. When it comes to inflammatory bowel disease, the practice is inconsistent. TME is associated with increased nerve injury with secondary erectile dysfunction, increased rates of pelvic sepsis (more pelvic space after TME than after close rectal dissection), more pelvis adhesions that can impair a second step reconstructive surgery or the reproductive function of women. ECCO guidelines recommend modified TME dissection - anterolateral close rectal dissection in combination with a posterior dissection in the TME plane in order to minimize genito urinary complications (15).

### *Stapled or Hand Sewn?*

IPAA can be done using stapling techniques or hand-sewn ones. There is also a variant, where a stapled pouch is reinforced by a continuous second layer of PDS 4-0. The results between the two alterantives are comparable in term of functional outcomes and complication rates .There is not a consensus about which type has the best results, current guidelines leave de decision at surgeon's discretion (2). The manual pouch is more time consuming. The decision must be made in concordance with the intestinal wall thickness. Patients operated for malignancy tend to have thinner walls than those who are non responders to treatment and have a long evolving disease, in this case a manual suture is more indicated (16).

### *Type of Pouch - Advantages/Disadvantages*

Regarding pouch construction, there are several types that must be taken into account. The most frequent is the "J-Pouch". "S" or "W"-shaped pouches can also be used in a reconstructive procedure. Literature reports of "K", "U" and "H"-shaped pouches can be found, but without wide spread among surgical practices (14).

The "J-Pouch" is easily constructed, this leading to decreased operative time compared

to the others. Patients with this type of pouch can have increased bowel movements and increased usage of anti-diarrhoeal medication. Seepage can be a complication of this setting.

The "W-Pouch" takes more operative time for construction and needs regular catheterisation for complete emptying, due to its higher volume.

The "S-Pouch" can come in handy when additional length is required in order to obtain a tension-free anastomosis. Higher rates for the need of catheterisations are encountered in patients with this pouch (14).

### *Timing of Stoma Closure*

Wong et al (18) performed a study on 1504 patients and concluded that the temporary loop ileostomy in patients with IPAA must be closed not before three months after the first procedure. This interval assures time for the patient to recover his nutritional status and general well-being.

For a three-stage procedure, the timing of terminal ileostomy closure, proctectomy, ileal pouch formation and anastomosis, with protective ileostomy are set to happen at least three months after the initial procedure. In the window of time following total colectomy, patients are generally weaned off medications and improved health and nutritional profile may be obtained. After two to three months, from step-two, the temporary ileostomy can be closed.

### *New Approaches*

Transanal total mesenteric excision (TaTME) is a trend in rectal cancer surgery that is trying to find usage for transanal proctectomy and IPAA surgeries for UC. The dissection is performed 2-3 centimetres above the dentate line and can be continued through the TME or by close mesorectal dissection. The anastomosis with the pouch can be performed mechanically using a stapler or by using a hand-sewn technique. The advantages include a minimal rectal mucosa and a close inspection of it, access to the distal rectum in a narrow pelvis,

apparently a lower conversion rate, shorter operative time and shorter hospital stay. The anastomotic leak rates tend to be the same (14). More comprehensive data needs to be analysed in order to determine that this is the procedure of choice.

### **Conclusion**

Surgical treatment of ulcerative colitis is associated with significant morbidity and mortality. In order to decrease morbidity rates, there are a few factors that can be influenced.

- First, it is the timing of surgical procedure. It is well known that delayed surgery may increase morbidity, length of stay, and hospital cost.
- Second, optimization of patient status, whenever possible, it is associated with improved postoperative results.
- And last but not least, when technical expertise is available, laparoscopic approach can be performed in most of the cases, bringing significant short- and long-term benefits compared to open surgery.

### *Conflict of Interests*

The authors declare that there is no conflict of interest.

### *Ethics Approval*

Not needed.

### **References**

1. Goldiș A, Lupușoru R, Gheorghe L, Gheorghe C, Trifan A, Dobru D, et al. Geographic Distribution, Phenotype and Epidemiological Tendency in Inflammatory Bowel Disease Patients in Romania. *Medicina (Kaunas)*. 2019;55(10):704.
2. Spinelli A, Bonovas S, Burisch J, Kucharzik T, Adamina M, Annesse V, et al. ECCO Guidelines on Therapeutics in Ulcerative Colitis: Surgical Treatment. *J Crohns Colitis*. 2022;16(2):179-189.
3. Wong DJ, Roth EM, Feuerstein JD, Poylin VY. Surgery in the age of biologics. *Gastroenterol Rep (Oxf)*. 2019;7(2):77-90.
4. Parks AG, Nicholls RJ. Proctocolectomy without ileostomy for ulcerative colitis. *Br Med J*. 1978;2(6130):85-88.
5. Peters WR. Laparoscopic total proctocolectomy with creation of ileostomy for ulcerative colitis: report of two cases. *J Laparoendosc Surg*. 1992;2(3):175-178.

6. Ionescu M, Dumitrașcu T, Stroescu C, Bărbuță S, Tomulescu V, Popescu I. Surgical treatment in ulcerative rectocolitis . Analysis of a 24 years experience of 50 patients. *Chirurgia (Bucur)*. 2004;99(3):125-135.
7. Dumitrașcu T, Ionescu M. [Restorative proctocolectomy]. *Chirurgia (Bucur)*. 2008;103(4):377-384.
8. Abdalla M. *Cancer and Reconstructive Surgery in Inflammatory Bowel Disease*. Linköping University Electronic Press; 2019.
9. Hyman N, Umanskiy K. *Difficult Decisions in Colorectal Surgery*. Springer; 2017.
10. Murphy B, Kavanagh DO, Winter DC. Modern surgery for ulcerative colitis. *Updates Surg*. 2020;72(2):325-333.
11. Luo WY, Singh S, Cuomo R, Eisenstein S. Modified two-stage restorative proctocolectomy with ileal pouch-anal anastomosis for ulcerative colitis: a systematic review and meta-analysis of observational research. *Int J Colorectal Dis*. 2020;35(10):1817-1830.
12. Mege D, Colombo F, Stellingwerf ME, Germain A, Maggiori L, Foschi D, et al. Risk Factors for Small Bowel Obstruction After Laparoscopic Ileal Pouch-Anal Anastomosis for Inflammatory Bowel Disease: A Multivariate Analysis in Four Expert Centres in Europe. *J Crohns Colitis*. 2019; 13(3):294-301.
13. Cheong C, Kim NK. Minimally Invasive Surgery for Rectal Cancer: Current Status and Future Perspectives. *Indian J Surg Oncol*. 2017;8(4):591-599.
14. da Luz Moreira A, Kiran RP, Lavery I. Clinical outcomes of ileorectal anastomosis for ulcerative colitis. *Br J Surg*. 2010;97(1):65-69.
15. Øresland T, Bemelman WA, Sampietro GM, Spinelli A, Windsor A, Ferrante M, et al. European evidence based consensus on surgery for ulcerative colitis. *J Crohns Colitis*. 2015;9(1):4-25.
16. Bong JW, Yoon YS, Lee JL, Kim CW, Park IJ, Lim SB, et al. Short-term Outcomes of Elective 2-Stage Restorative Proctocolectomy for Ulcerative Colitis in Korea: Does Laparoscopy Have Benefits? *Ann Coloproctol*. 2020;36(1):41-47.
17. Wong KS, Remzi FH, Gorgun E, Arrigain S, Church JM, Preen M, et al. Loop ileostomy closure after restorative proctocolectomy: outcome in 1,504 patients. *Dis Colon Rectum*. 2005;48(2):243-50.