

## **Surgical Repair of Iatrogenic Duodenal Injuries with a Roux-en-Y Duodenojejunostomy: A Physiology-oriented Approach**

**Dimitrios Symeonidis<sup>1</sup>, Athina A. Samara<sup>1</sup>, Alexandros Diamantis<sup>1</sup>, Ioanna-Konstantina Sgantzu<sup>2</sup>, Theodoros Floros<sup>1</sup>, Dimitrios Zacharoulis<sup>1</sup>**

<sup>1</sup>Department of Surgery, University Hospital of Larissa, Greece

<sup>2</sup>Department of Radiology, University Hospital of Larissa, Greece

\*Corresponding author:  
Athina A. Samara, MD  
Department of Surgery  
University Hospital of Larissa  
Mezourlo Hill, Larissa, Greece, 41334  
Tel. +302413501701  
E-mail: at.samara93@gmail.com

### **Rezumat**

*Repararea chirurgicală a leziunilor duodenale iatrogene prin duodeno-jejunostomie pe ansă Roux-en-Y: o abordare orientată spre fiziologie*

*Introducere:* Leziunile duodenale iatrogene reprezintă o afecțiune cu morbiditate și mortalitate ridicate. Managementul este încă unul controversat, fără un consens între experți în ceea ce privește tratamentul optim. Scopul prezentului studiu este testarea și evaluarea rezultatelor unei anumite tehnici de reconstrucție.

*Materiale și metode:* Studiul include 4 pacienți (2 bărbați și 2 femei) cu vârsta medie de 83 de ani cu leziuni duodenale iatrogene, la care s-a practicat repararea chirurgicală a perforației duodenale prin duodenojejunostomie în două straturi cu ansă jejunală Roux-en-Y.

*Rezultate:* Trei din patru pacienți (75%) au avut o recuperare rapidă și necomplicată (durata medie de spitalizare postoperatorie de 13 zile), în timp ce al patrulea pacient a decedat în UTI din cauza SDRĂ trei săptămâni mai târziu, fără, totuși, dovezi ale unei fistule anastomotice.

*Concluzie:* O varietate de tehnici de reparare chirurgicală au fost propuse până în prezent cu rezultate controversate. Anastomoza duodeno-jejunală pe ansă Roux-en-Y pare să îndeplinească toate condițiile pentru un rezultat anastomotoc de succes și s-a dovedit eficientă în cazul pacienților incluși în studiu.

**Cuvinte cheie:** leziuni duodenale iatrogene, ansa jejunală Roux-en-Y

Received: 14.04.2022  
Accepted: 10.06.2022

## Abstract

*Introduction:* Iatrogenic duodenal injuries represent a condition associated with high morbidity and even mortality. Management is still controversial with a lack of consensus among experts regarding the optimal treatment. The purpose of the present study was to test and assess the results of a certain reconstruction technique.

*Materials and Methods:* Four patients (2 males and 2 females) of a mean age of 83 years with iatrogenic duodenal injuries underwent surgical repair of the duodenal perforation, with a two-layer duodenojejunostomy and a Roux-en-Y jejunal loop.

*Results:* Three out of four patients (75%) had a rapid and uncomplicated recovery (13 days mean postoperative length of hospital stay), while the fourth patient died in the ICU due to ARDS three weeks later, without however evidence of anastomotic leak.

*Conclusion:* A variety of surgical repair techniques have been proposed to date; however, with controversial results. A repair using an isolated jejunal Roux-en-Y loop seems to fulfill all the optimal prerequisites for a successful anastomotic outcome and proved efficient in its certain form for the given patient sample.

Key words: iatrogenic duodenal injuries, Roux-en-Y jejunal loop

## Introduction

Iatrogenic duodenal injuries, leading either to a free perforation into the peritoneal cavity or to a contained abscess within the retroperitoneum, represent a rare condition with significant associated morbidity and even mortality. Literature reports report the mortality of such injuries as high as 25% (1). Generally, iatrogenic injuries to this specific area of the gastrointestinal tract occur either as a dismal consequence of an upper GI endoscopy or inadvertently, during a surgical operation in the upper abdomen. Regarding endoscopic injuries, the relative risk is substantially increased when invasive endoscopic maneuvers are employed concurrently with the endoscopy itself, either in the form of Endoscopic Retrograde Cholangiopancreatography (ERCP) usually complemented with sphincterotomy when attempts to control a bleeding site onto the duodenal mucosa are undertaken, or when a polypectomy is carried out (2-3). However, apart from the endoscopic injuries, surgical procedures in the upper abdomen where occasionally copious surgical maneuvers take place in proximity to the duodenum, render the duodenum at risk of an inadvertent injury (4).

The first description of a duodenal perforation on the background of a peptic ulcer was reported in 1688, while the first successful surgical repair of a duodenal perforation was made in 1894 (5-6). The field is further complicated when an iatrogenic injury is a case where possible medico-legal consequences may occur. Several decades later, the management of duodenal perforations remains controversial, with no current consensus among experts regarding the optimal treatment. Traditionally, surgery is considered the most appropriate treatment approach; however, recently less invasive treatment options such as endoscopic approaches have been tried as well, usually yielding controversial outcomes (7-8). Similarly, literature data on the results of surgical management are scarce. Therefore, recommendations regarding the optimal timing of the repair or the appropriate type of reconstruction are lacking, and ultimately, management tends to be directly dependent upon the clinician's preference and expertise.

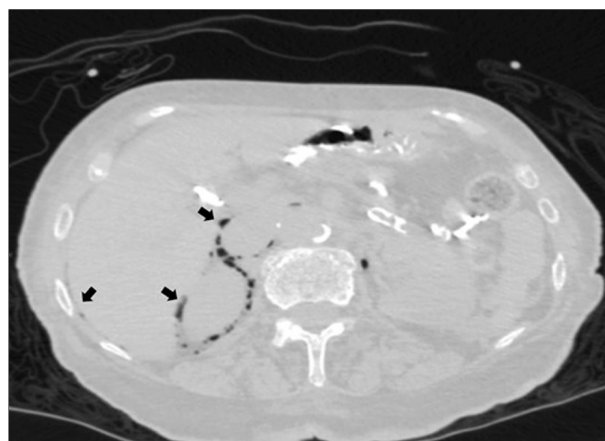
In the present report, we aimed to present, propose and ultimately test a certain type of surgical reconstruction for duodenal injuries upon the paradigm of four consecutive iatrogenic duodenal injury patients treated in our department.

## Materials and Methods

Internal board approval and ethics committee permission had been granted before the initiation of the present study. Between April 2019 and March 2020, four (4) patients (mean age: 83 years old (range: 77-89 years) - male/female ratio 1:1) with iatrogenic duodenal injuries were referred to our department for further and definite management by the same surgical team. Patient demographics, relevant medical history, clinical presentation, operation reports and all data yielded out of the radiological and laboratory investigation conducted were analyzed and recorded prospectively (*Table 1*).

The first patient was a 78-year-old Caucasian male who was referred to our department with a high output enterocutaneous fistula. Attempts to dissect free the inflamed gallbladder from the duodenal wall during an open cholecystectomy resulted in a duodenal perforation. An attempt of primary repair of the perforation by direct suturing during the index operation proved unsuccessful, as the output of the abdominal drain even from the 1st postoperative day had enteric like contents of high volume. In our department, an initial conservative approach was decided upon with fasting, continuous nasogastric tube aspiration and broad-spectrum antibiotics. However, as clinical and biochemical evidence of sepsis ensued, a decision was made for a surgical exploration.

The second patient was an 89-year old Caucasian female with clinical signs of acute abdomen, such as rigidity and diffuse abdomi-



**Figure 1.** A contrast-enhanced CT (Computer Tomography) with free air within the peritoneal cavity

nal tenderness upon palpation, 12 hours after a reportedly uneventful ERCP. A Magnetic Resonance Cholangiopancreatography (MRCP) verified choledocholithiasis was the indication for the endoscopic clearance of the common bile duct via ERCP. An urgent contrast-enhanced CT (Computer Tomography) (*Fig. 1*) that was conducted based on the patient's acute symptoms revealed free air within the peritoneal cavity consisted of a hollow viscus perforation, leading to a decision for urgent laparotomy.

The third patient was a 77-year old Caucasian female presenting to the emergency department with a four (4) day history of melena complemented with three recent episodes of hematemesis. An urgent upper GI endoscopy revealing a bleeding ulcer on the lateral duodenal wall was followed by endoscopic attempts to control the ongoing

**Table 1.** Case presentation

Case	1	2	3	4
Age	78	89	77	88
Sex	Male	Female	Female	Male
Underlying pathology	Post cholecystectomy	Post ERCP	Duodenal Ulcer	Duodenal Ulcer
Delay from diagnosis to intervention	30 days	Immediate	Immediate	Immediate
Post-operative length of stay	12 days	13 days	15 days	18 days
Complication	None	None	Atrial fibrillation	Death
Oral feeding	5 <sup>th</sup> postoperative day	3 <sup>rd</sup> postoperative day	5 <sup>th</sup> postoperative day	5 <sup>th</sup> postoperative day
ASA score	II	II	II	IV

ASA score: American Society of Anesthesiology Physical Status Classification System

bleeding, with adrenaline infusion and clip placement onto the bleeding vessel proved successful. However, soon after the endoscopy the patient developed clinical signs of acute abdomen and therefore an exploratory laparotomy was decided upon.

The fourth patient, an 88-year old Caucasian male presented to the emergency department with multiple episodes of hematemesis and hemodynamic instability. After the immediate resuscitation with intravenous (IV) crystalloid fluids and blood transfusions, an emergency upper GI endoscopy was performed, revealing a bleeding ulcer on the anterior duodenal wall. The endoscopic attempts to achieve hemostasis did not achieve the desired outcome and further resulted in a perforation of the duodenal wall. Therefore an emergency laparotomy was decided upon.

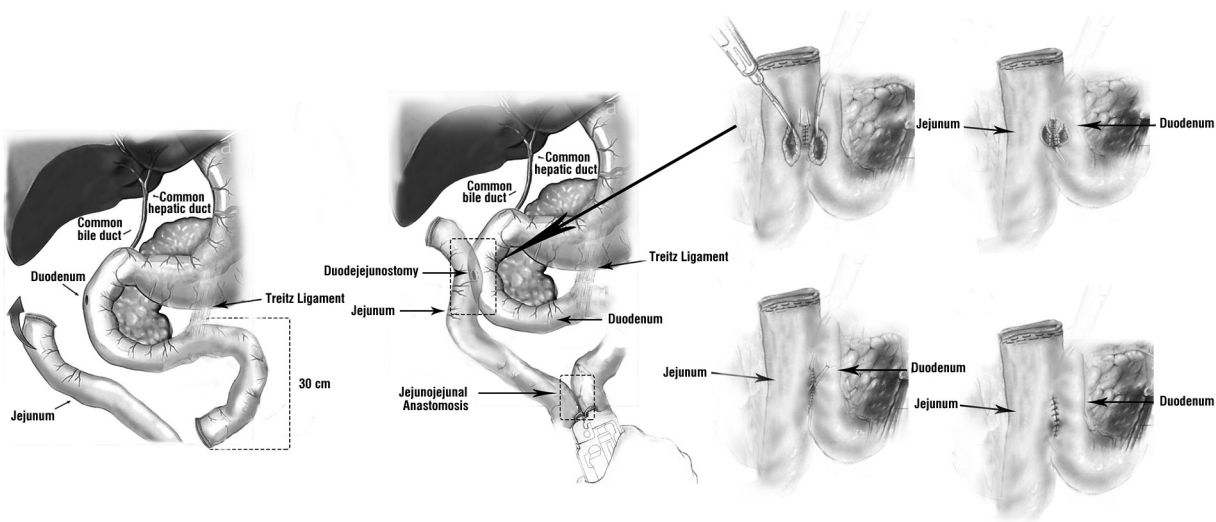
**Surgical Technique**

In all four patients, the same operative principles were followed (*Fig. 2*). Specifically, a midline supra-umbilical incision was used to gain access into the peritoneal cavity, performing copious lavage with several liters of normal saline solution. The identification of the exact site of the perforation onto the

duodenal wall was commonly facilitated by a generous Kocher maneuver, which was performed in all patients, and the perforation site onto the duodenal wall was appropriately debrided. Due to adequate recognition of the perforation site, there was no need for intra-operative imaging with indocyanine green (ICG) fluorescence.

Next, an isolated Roux en Y jejunal loop was created. For this purpose, the jejunum was stapled and divided 30 cm distally of the ligament of Treitz. A window large enough to allow the retrocolic passage of the stapled distal jejunal loop was then carefully created in the transverse mesocolon, taking special care to avoid injuring the middle colic vessels usually utilizing the trans-illumination technique. Following this, the retrocolic jejunal loop was mobilized and aligned appropriately to lie just adjacent to the perforation of the Kocherized duodenum.

An opening of the same diameter as the perforation in the duodenum was then made on the jejunal loop. A side to side two layer anastomosis, for example a duodenojejuno-stomy, was then made according to the principles described by Shrikhande et al (9) in their proposed technique regarding the pancreaticojejunostomy for restoring continuity



**Figure 2.** Step-by-step operative technique

of the gastrointestinal tract after a Whipple's procedure. In our case however, the perforation hole on the duodenal wall corresponds to the pancreatic duct as described by Shrikhande et al.

Specifically, the first step involves the placement of three to six depending on the diameter of the perforation, 4.0 PDS (Ethicon; Johnson and Johnson) on the anterior aspect of the circumference of the perforation defect, starting from the duodenal serosa to the perforation defect. Then, a similar row of sutures was placed at the posterior part of the perforation defect, transversing the needle from the perforation defect to the duodenal serosa posterior to the perforation defect. All sutures are held intact along with their needles for future use on the jejunal loop. To avoid confusion each of these distinct layers is separated by a gauze on the operation field.

The next step involved the creation of the posterior outer layer of the anastomosis by placement of interrupted 4.0 PDS (Ethicon; Johnson and Johnson) sutures beginning on the posterior aspect of the duodenal wall. They are placed approximately 1 cm away from the perforation defect and approach the seromuscular layer of the jejunal wall 1 cm posteriorly to the opening onto the jejunal loop. After the placement of all posterior outer layer sutures, these interrupted sutures were all tied gently.

The following step involved the creation of the posterior inner layer of the anastomosis. Then, the needles of the preplaced sutures of the posterior part of the duodenal defect were used and transverse it in a full-thickness manner in a direction from the jejunal serosa to the opening onto the jejunal wall. After the placement of all inner posterior sutures, the sutures were gently tied. The same principles were applied for the creation of the anterior inner layer, where the needles of the anteriorly preplaced sutures were passed through the opening onto the jejunal loop. They were then guided in a full-thickness manner out of the serosa and tied.

The final step of the anastomosis was the creation of the anterior outer layer, with

interrupted sutures beginning on the anterior aspect of the duodenum and coming onto the anterior aspect of the jejunal serosa, concluding the two-layer anastomosis. The gastrointestinal tract continuity was also restored with a stapled side to side jejunojunction leaving a Roux limb of approximately 25 cm.

## Results

The median operative time was 180 minutes, without any intraoperative incidents. Three out of four patients (cases 1, 2 and 3) (75%) had a rapid and complete recovery. The mean postoperative length of stay was 13 days (range: 12-15 days). The fourth patient unfortunately passed away while in the ICU unit due to pulmonary complications on the 18<sup>th</sup> postoperative day, however without showing signs of anastomotic leak.

More specifically, the first patient had a rapid and complete recovery. He was weaned off the nasogastric tube on the 5<sup>th</sup> postoperative day and was able to recommence and adequately tolerate oral feeding. He was discharged on the 12<sup>th</sup> postoperative day; there are no recorded readmissions in an 18-month follow-up. Similarly, the second patient had an uneventful postoperative recovery, having oral feeding recommence on the 3<sup>rd</sup> postoperative day and being discharged on the 13<sup>th</sup> postoperative day. In a follow up period of 16 months, she remained symptom-free.

The third patient had the nasogastric tube removed on the 3<sup>rd</sup> postoperative day with oral feeding recommenced on the 4<sup>th</sup> postoperative day. The patient was discharged on the 15<sup>th</sup> post-operative day. The fourth patient was transferred postoperatively to the ICU due to respiratory acidosis documented in patients' blood gases. As there were no signs of anastomotic leakage, the patient was started on enteric nutrition through a feeding nasogastric tube on the 5<sup>th</sup> post-operative day. However, the patient died on the 18<sup>th</sup> postoperative day due to Acute Respiratory Distressed Syndrome (ARDS).

## Discussion

The prompt recognition of all duodenal perforations - including the iatrogenic perforation - is vital for an optimal outcome as it is associated with a lower incidence of systemic inflammatory response syndrome (SIRS), decreased need for ICU level care and shorter length of hospital stay (10-11). Conversely, delayed diagnosis can lead to higher morbidity and mortality rates (12). In general, a multiple detector computed tomography (MDCT) scan with oral contrast is the most sensitive and specific diagnostic modality (13-14). A multi-disciplinary team approach, which involves early consultation with the surgical team and an accurate description of the mechanism of the injury, is crucial for optimizing clinical outcomes and assisting in surgical decision making (15-16).

Iatrogenic duodenal injuries include injuries that can take place during surgical operations in proximity to the duodenum, following ERCP or an upper GI endoscopy. Several systems have been proposed to classify injuries, especially after ERCP based on the mechanism, location and severity of the injury (17). The system proposed by Stapfer et al. is currently the most widely utilized. According to this classification system, duodenal perforations are classified as Type I: perforations of the lateral or medial duodenal wall usually caused by the endoscope remote from the ampulla; Type II: peri-ampullary injury; Type III: injury of the distal bile duct usually caused by wire or basket instrumentation; Type IV: the presence of retroperitoneal air alone (8).

Generally, the management of duodenal injuries appears rather challenging due to their unique characteristics. The duodenum is the first part of the small intestine located in the retroperitoneum, and is strongly associated with the biliary tree, sharing its marginal blood supply with the pancreas (18). In terms of intraluminal contents, the duodenum is transversed by an increased volume of highly active exocrine pancreatic enzymes and bile, while the intraluminal pressures are among the highest recorded

within the whole small intestine (18).

When a duodenal perforation is recognized, the obvious dilemma is whether a conservative approach is appropriate or immediate surgical management is mandatory. The decision on the optimal management is directly dependent on the mechanism of the injury, the exact site, the degree of the leak, the patient's clinical condition and whether a highly specialized team is available on site (19-21). A recently published systematic review and meta-analysis highlighted the significance of the initial management of patients with post-ERCP perforations. In cases treated with a surgical or an endoscopic approach, the patient should immediately be evaluated by a referral center (20).

Initial conservative management include resuscitation with intravenous fluids, fasting, broad-spectrum antibiotics, pneumoperitoneal decompression and endoscopic repair if possible (22). Endoscopic repair using fibrin glue, endoloops and endoclips or an over the scope clipping device have all been proposed with promising results (21). Conversely, surgery appears as the only definite treatment in cases where non-operative management has failed. In geriatric trauma patients, it is recommended that they receive aggressive care during the initial phase of treatment, to have the most favourable outcomes (23).

Several surgical alternatives have been proposed. Early diagnosed perforations where limited contamination has occurred can be managed by primary repair with direct suturing in one or two layers, either transversely or longitudinally. Aiming to reduce leakage rates, reinforcing the suture line with a jejunal serosal or an omental patch have been attempted as well (24). However, in patients at high risk for leakage and subsequent fistula formation (i.e. poor vascularization and increased local inflammation leading to inability to safely mobilize the duodenum via a Kocher maneuver), primary repair seems inadequate to guarantee a safe and complication-free recovery (25).

Under these circumstances, the duodenal diverticulization has been proposed, which is a

procedure that includes duodenal repair, distal Billroth II gastrectomy, decompressive duodenostomy and peri-duodenal drainage (26). However, this is a relatively time-consuming procedure associated with increased morbidity. These conditions render this procedure at times inappropriate, especially for hemodynamically unstable patients with multiple comorbidities (26). Similarly, a pyloric exclusion which includes repair of the injury, pyloric occlusion, common bile duct drainage and a gastrojejunostomy has traditionally been used in the management of complicated duodenal injuries, aiming to protect the duodenal repair and prevent septic abdominal complications. However, it is associated with increased length of hospital stay while no survival benefit has been documented, particularly in patients with severe duodenal injuries (27). Furthermore, in cases of severe pancreaticoduodenal injury a surgical approach with pancreaticoduodenectomy (Whipple's procedure) has been reported as formidable with a high mortality rate (28).

It becomes more than clear that the aforementioned techniques have several drawbacks thus limiting their clinical usefulness. Considering the unique physiological characteristics of this distinct part of the small intestine, a procedure that could decompress the increased duodenal intraluminal pressures, drain internally the highly active duodenal contents and bypass the alimentary tract stream from the site of the injury (for example the duodenum) would appear as ideal. Within this framework, a duodenojejunostomy with a Roux-en-Y reconstruction can fulfill these prerequisites. This specific approach has already been tested and published in the past, while the authors limit the indications to hemodynamic stable patients with healthy and well-vascularized injury margins, well preserved duodenal medial wall, intact papilla of Vater and undamaged pancreas (29-30).

In the present report, we aimed to take the concept of repairing an iatrogenic duodenal injury with a Roux en Y jejunal loop one step further. As the local conditions for performing an optimal anastomosis are not always ideal

at the background of local sepsis, we used the experience gained from the pancreatic anastomoses to increase the success rate of repair. In general, a pancreaticojejunostomy is a high risk for leakage anastomosis, and a delicate technique should be employed to achieve the best possible outcome. In this direction, in the present patient sample (4 patients) we followed the principles for the duodenojejunostomy that apply for the pancreaticojejunostomy, aiming to bypass the handicaps of a high-risk repair.

In the present study, we used this certain anastomosis technique in four consecutive patients with iatrogenic duodenal injuries presented and managed surgically in our department. The results of the present report suggest the adequacy and efficacy of the proposed technique in the given patient sample. The small number of patients included in this study represents an obvious limitation. In this context, the generalization of our results is limited. However, data regarding iatrogenic injuries of the duodenum are scarce and case series reporting data on management of these injuries include limited numbers of patients. Prospective case series with a larger number of patients are needed to assess more objectively the safety, feasibility and efficacy of the proposed technique.

## Conclusions

In conclusion, iatrogenic duodenal injuries are a condition of increased morbidity and mortality rates, usually with dismal medico-legal extensions. A variety of surgical repair techniques have been proposed to date; however with controversial results. A repair using an isolated jejunal Roux-en-Y loop seems to fulfill all the optimal prerequisites for a successful anastomotic outcome and proved efficient in our proposed form for the given patient sample.

## Conflict of Interest

The authors have no conflicts of interest to declare about the present study.

## Funding

There was no funding in this study.

## Informed consent

All the patients included in this study have provided informed consent.

## References

1. Ansari D, Torén W, Lindberg S, Pyrhönen HS, Andersson R. Diagnosis and management of duodenal perforations: a narrative review. *Scand J Gastroenterol.* 2019;54(8):939-944.
2. Langerth A, Isaksson B, Karlson BM, Urdzik J, Linder S. ERCP-related perforations: a population-based study of incidence, mortality, and risk factors. *Surg Endosc.* 2020;34(5):1939-1947.
3. Li DF, Yang MF, Chang X, Wang NN, Tan FF, Xie HN, et al. Endocut versus conventional blended electrosurgical current for endoscopic biliary sphincterotomy: a meta-analysis of complications. *Dig Dis Sci.* 2019;64(8):2088-2094.
4. Nehra A, Godara R. The management of duodenal perforation: change over time. a case series and literature review. *Hellenic J Surg.* 2019; 91:159-164.
5. Dean HP. A Case of Perforation of a Chronic Ulcer of the Duodenum Successfully Treated by Excision: Death Two Months later from Acute Intestinal Obstruction by a Band. *Br Med J.* 1894;1(1741):1014-5.
6. Fleming BL. Acute perforation of duodenal ulcers: causes of death and a consideration of treatment. *JAMA.* 1931;97(1):6-11.
7. Machado NO. Management of duodenal perforation post-endoscopic retrograde cholangiopancreatography. When and whom to operate and what factors determine the outcome? A review article. *JOP.* 2012;13(1):18-25.
8. Stapfer M, Selby RR, Stain SC, Katkhouda N, Parekh D, Jabbour N, et al. Management of duodenal perforation after endoscopic retrograde cholangiopancreatography and sphincterotomy. *Ann Surg.* 2000;232(2):191-8.
9. Shrikhande SV, Kleeff J, Büchler MW, Friess H. Pancreatic anastomosis after pancreaticoduodenectomy: how we do it. *Indian J Surg.* 2007;69(6):224-9.
10. Bill JG, Smith Z, Brancheck J, Elsner J, Hobbs P, Lang GD, et al. The importance of early recognition in management of ERCP-related perforations. *Surg Endosc.* 2018;32(12):4841-4849.
11. Tarasconi A, Coccolini F, Biffi WL, Tomasoni M, Ansaloni L, Picetti E, et al. Perforated and bleeding peptic ulcer: WSES guidelines. *World J Emerg Surg.* 2020;15:3.
12. Mousa HM, Hefny AF, Abu-Zidan FM. Life-threatening duodenal perforation complicating endoscopic retrograde cholangiopancreatography: A case series. *Int J Surg Case Rep.* 2020;66:404-407.
13. Kim HC, Yang DM, Kim SW, Park SJ. Gastrointestinal tract perforation: evaluation of MDCT according to perforation site and elapsed time. *Eur Radiol.* 2014;24(6):1386-93.
14. Pouli S, Kozana A, Papakitsou I, Daskalogiannaki M, Raissaki M. Gastrointestinal perforation: clinical and MDCT clues for identification of aetiology. *Insights Imaging.* 2020;11(1):31.
15. Miller R, Zbar A, Klein Y, Buyeviz V, Melzer E, Mosenkis BN, et al. Perforations following endoscopic retrograde cholangiopancreatography: a single institution experience and surgical recommendations. *Am J Surg.* 2013;206(2):180-6.
16. Baron TH, Wong Kee Song LM, Zielinski MD, Emura F, Fotoohi M, Kozarek RA. A comprehensive approach to the management of acute endoscopic perforations (with videos). *Gastrointest Endosc.* 2012;76(4):838-59.
17. Symeonidis D, Zacharoulis D, Diamantis A, Samara AA, Magouliotis DE, Floros T, et al. Iatrogenic Bile Duct Injuries: A Critical Appraisal of Classification Systems. *Chirurgia (Bucur).* 2021;116(5):524-532.
18. Weale RD, Kong VY, Bekker W, Bruce JL, Oosthuizen GV, Laing GL, et al. Primary repair of duodenal injuries: a retrospective cohort study from a major trauma centre in South Africa. *Scand J Surg.* 2019;108(4):280-284.
19. Cirocchi R, Kelly MD, Griffiths EA, Tabola R, Sartelli M, Carlini L, et al. A systematic review of the management and outcome of ERCP related duodenal perforations using a standardized classification system. *Surgeon.* 2017;15(6):379-387.
20. Samara AA, Diamantis A, Perivoliotis K, Mavrovounis G, Symeonidis D, Baloyiannis I, et al. Surgical versus non-operative initial management of post-endoscopic retrograde cholangiopancreatography perforation: a systematic review and meta-analysis. *Ann Gastroenterol.* 2022;35(1):95-101.
21. Vezakis A, Fragulidis G, Polydorou A. Endoscopic retrograde cholangiopancreatography-related perforations: Diagnosis and management. *World J Gastrointest Endosc.* 2015;7(14):1135-41.
22. Prachayakul V, Aswakul P. Endoscopic retrograde cholangiopancreatography-related perforation: management and prevention. *World J Clin Cases.* 2014;2(10):522-7.
23. Søreide K, Desserud KF. Emergency surgery in the elderly: the balance between function, frailty, fatality and futility. *Scand J Trauma Resusc Emerg Med.* 2015;23:10.
24. Turner RC, Steffen CM, Boyd P. Endoscopic duodenal perforation: surgical strategies in a regional centre. *World J Emerg Surg.* 2014;9(1):11.
25. Jansen M, Du Toit DF, Warren BL. Duodenal injuries: surgical management adapted to circumstances. *Injury.* 2002;33(7):611-5.
26. Berne CJ, Donovan AJ, White EJ, Yellin AE. Duodenal "diverticulization" for duodenal and pancreatic injury. *Am J Surg.* 1974;127(5):503-7.
27. DuBose JJ, Inaba K, Teixeira PG, Shifflett A, Putty B, Green DJ, et al. Pyloric exclusion in the treatment of severe duodenal injuries: results from the National Trauma Data Bank. *Am Surg.* 2008;74(10):925-9.
28. Asensio JA, Petrone P, Roldán G, Kuncir E, Demetriades D. Pancreaticoduodenectomy: a rare procedure for the management of complex pancreaticoduodenal injuries. *J Am Coll Surg.* 2003;197(6):937-42.
29. Cukingnan RA Jr, Culliford AT, Worth MH Jr. Surgical correction of a plateral duodenal fistula with the Roux-Y technique: report of a case. *J Trauma.* 1975;15(6):519-23.
30. Manenti A, Melegari G, Zizzo M, Farinetti A. The Roux-en-Y jejunal loop for duodenal repair. *J Visc Surg.* 2018;155(5):435-436.